

Microanatomical Patterns of Renal Amyloidosis in Domestic Sheep, Iran

¹Keivan Jamsidi and ²Ozlem Ozmen

¹*Department of Pathology, Faculty of Veterinary Medicine, Islamic Azad University, Garmsar Branch, Tehran, Iran*

²*Department of Pathology, Faculty of Veterinary Medicine, Mehmet Akif Ersoy University, Istiklal Yerleskesi, 15030 Burdur, Turkey*

Key words: Amyloidosis, Iran, kidney, sheep, CR

Corresponding Author:

Keivan Jamsidi

Department of Pathology, Faculty of Veterinary Medicine, Islamic Azad University, Tehran, Garmsar Branch, Iran

Page No.: 15-20

Volume: 10, Issue 3, 2017

ISSN: 1993-5412

Veterinary Research

Copy Right: Medwell Publications

Abstract: Amyloidosis represents a heterogenous group of diseases that have in common the deposition of fibrils composed of proteins of beta-pleated sheet structure, a structure which can be specifically identified by histochemistry using the Congo red (CR) or similar stains. Between October 2013 to April 2014 (6 months) different patterns of renal amyloidosis was diagnosed on histopathological examination of kidneys belong to 196 out of 7065 slaughtered sheep subjected to postmortem examination. Microscopic examination of renal tissue sections stained with Hematoxylin-Eosin (H&E) and CR staining techniques, revealed 3 patterns of renal amyloid deposition including glomerular (22.72%), medullary (68.18%) and vascular (9.09%). Renal Medullary Amyloidosis (RMA) was detected as the most prevalence pattern of renal amyloidosis in domestic sheep in Iran.

INTRODUCTION

In general term amyloidosis is described as a diverse group of diseases in which pathologic fibrillary proteinaceous material known as amyloid is deposits extracellularly as amorphous and congophilic substance in various tissues and organs. By Hematoxylin-Eosin (H&E) staining these deposited proteinaceous substances, are seen as hyaline aggregates but regardless of their chemical nature, reveal orange colored staining by Congo Red (CR) staining. CR positive areas when viewed in cross-polarized light, show green birefringence (Murphy *et al.*, 2001).

In human and animal pathology, >20 amyloid protein and 8 amyloid protein precursors, respectively are known to have the ability to aggregate, insolubilize and deposit in different tissues and organs as amyloid (Rings and

Garry, 1988; Seifi *et al.*, 1997; Sato *et al.*, 1981; Shtrasburg *et al.*, 2005). In human being the most common form of amyloid is AL amyloid which is immunoglobulin light chain derivative. While, AA Amyloid is the most common form of Amyloid, found in animals (Jones, 1985; Seifi *et al.*, 1997; Sato *et al.*, 1981; Shtrasburg *et al.*, 2005; Nieto *et al.*, 1995). A Amyloidosis have been documented in a wide variety of domestic animal species (including canine, equine, bovine, avian and less frequently porcine and feline) (Cotran *et al.*, 1999; Kisilevsky, 1990; Jakob, 1971; Landman *et al.*, 1997; Rideout *et al.*, 1989; Gruys, 1977; Bancroft and Gamble, 2008) and wild mammalian and avian species including cheetah (Yoshida *et al.*, 2009; Farnsworth and Miller, 1985), Siberian tigers (Lucke and Hunt, 1965), mink (Tham and Bunn, 1992), Dorcas gazelle (Jubb *et al.*, 2007), mountain gazelle (Linke *et al.*,

1986; Sato *et al.*, 1981) and anatidae (Chew *et al.*, 1982). AA Amyloidosis has also been reported in small ruminants as in wild bighorn sheep (*Ovis canadensis*) (Hayden *et al.*, 1988) and Dall sheep (*Ovisdallis*) (Schulze *et al.*, 1998) but rare studies have been reported in domestic sheep and goat and only refer to single cases (Zschesche and Jakob, 1989; Picken, 2001; Sei *et al.*, 1997; Westermarck *et al.*, 1979; Mensua *et al.*, 2003). Any tissue and organ is said to be involved in AA amyloidosis but renal amyloidosis occurs with greatest frequency (Johnson and Jamison, 1984; Munson, 1993). Since, deposition of amyloid proteinaceous substance in glomerular capillary tuft leads to disruption of the glomerular filtration barrier with subsequent proteinuria and related pathologic conditions, thus, renal involvement is considered to have the most serious consequences. Moreover, peritubular interstitial deposition of amyloid causes ischemia and pressure atrophy of nephrons which finally, leads to interstitial scarring with subsequent clinical signs of renal failure (Munson, 1993).

Although, Renal Medullary involvement of Amyloidosis (RMA) is rare in human being (Monaghan, 1982) and most animals (Munson, 1993) but has been reported as the predominant form of renal amyloidosis in cats (Linke *et al.*, 1984; Munson, 1993; Hadlow and Jellison, 1962), cattle (Blunden and Smith, 1992; DiBartola *et al.*, 1989; Munson, 1993) and particularly in Dorcas gazelle (Mensua *et al.*, 2003). In cattle, renal involvement of amyloidosis varies from predominantly glomerular to predominantly medullary form (Blunden and Smith, 1992; DiBartola *et al.*, 1989). In cattle as in other species, the glomerular form of amyloidosis can lead to the nephrotic syndrome (Blunden and Smith, 1992; Yoshida *et al.*, 2009; Crawford *et al.*, 1989) but the medullary form of amyloidosis is usually not diagnostic clinically (DiBartola *et al.*, 1989). In Dorcas gazelle, the pattern of renal amyloidosis is unusual as the deposition was reported to be most prominent in medullae with sparing of glomeruli and little or no involvement of cortical interstitium (Jubb *et al.*, 2007).

In domestic sheep and goat the anatomical pattern of renal amyloidosis with no regard to species, breed and sex was similar and the only difference was observed in severity. In these species glomeruli were found to be the most predominant site for amyloid deposition. Capillary walls and mesangium in the glomerular tuft were observed as the main place for amyloid deposition (Jubb *et al.*, 2007).

This study because of the lack of adequate information relating to renal form of amyloidosis in small ruminants in Iran was tailored to find out the relative prevalence and anatomic pattern(s) of renal involvement in naturally occurring amyloidosis in sheep.

MATERIALS AND METHODS

This abattoir-based study was conducted in Qom, Iran, during the October 2013 to April 2014 (6 months). Out of 18004 heads of slaughtered sheep, 7065 heads were randomly selected and subjected to total postmortem examination. Finally, renal specimens from 196 animals (from both sexes) with macroscopic lesions were selected, condemned and removed from human consumption cycle. Regarding to sex, animals were divided into three groups: <1 year old, between 1-2 year old and above 2 years old. Proper renal tissue sample from each animal was obtained in adequate size (1×1×0.5 cm) and fixed in 10% neutral buffered formalin, dehydrated and finally, embedded in paraffin wax. Four-micrometer-tick sections were stained through H&E and CR staining procedures (Blunden and Smith, 1992). Microscopic examination was conducted by the help of light microscopy for both H&E and CR stained sections and polarized light microscopy for CR stained sections only.

RESULTS

In microscopic examination, the presence of amyloid deposits was detected in 44 out of 196 (22.45%) kidneys (Table 1 and 2). In this study, regardless of sex and age, in 44 out of 196 animals (22.45%), amyloid deposits were noted with the highest percentage in female sheep (40.90%) aged from 1-2 year old and the lowest percentage (2.28%) in male sheep aged <1 year old and above 2 years old.

Glomerular pattern of renal amyloidosis: Glomerular amyloidosis was observed only in female animals (10/44) as both segmental (Fig. 1 and 2) and global (Fig. 3 and 4) forms and as eosinophilic and CR positive deposits within glomeruli (22.72%). Global form occupied entire glomerular tuft and compressing and distorting the normal structural architecture. Global amyloidosis which were observed in severe form of glomerular pattern of amyloidosis were hypocellular but periglomerular infiltration of mononuclear cells were occasionally noted (Fig. 3 and 4). When both H&E and CR techniques were used, no amyloid deposits were observed in the cortical interstitium.

Medullary pattern of renal amyloidosis: In (30/44) animals (68.18%) renal medullary amyloidosis was observed as multifocal amyloid deposits around the vasa recta and venous plexuses which could cause atrophy and disappearance of adjacent collecting ducts and loops of Henle. This lesion was observed in both male and female sheep with the lowest value in male sheep aged <1 year and those above 2 years old (1/44) (2.28%) and the

Table 1: Number of animals with condemned kidneys on the base of sex, approximate age and presence of amyloidosis

Sex	Approximate age (Years old)	No. of animals with condemned kidneys	Presence of amyloidosis	Percentage
Male	≤1	8	1	2.28
	1-2	4	2	4.54
	≥2	13	1	2.28
Female	≤1	27	7	15.90
	1-2	74	18	40.90
	≥2	70	15	34.10
Total		196	44	100.00

Table 2: Histological patterns of renal amyloid depositions

Sex	Approximate age (Years old)	Glomeruli	Medullas	Blood vessels
Male	≤1	0	1	0
	1-2	0	2	0
	≥2	0	1	0
Female	≤1	2	5	0
	1-2	4	11	3
	≥2	4	10	1
Total		10	30	4

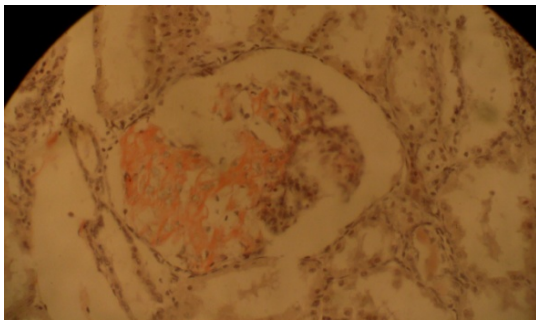


Fig. 1: Female sheep, 1-2 year old. Glomerular pattern of renal amyloidosis, segmental form. Congo red staining. Light microscopy×10

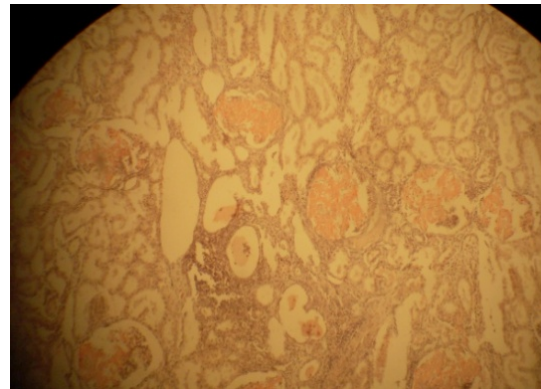


Fig. 3: Female sheep, 1-2 year old. Glomerular pattern of renal amyloidosis, Global form (arrow). Note granular cast within the tubule (arrow head). Congo red staining. Light microscopy×4

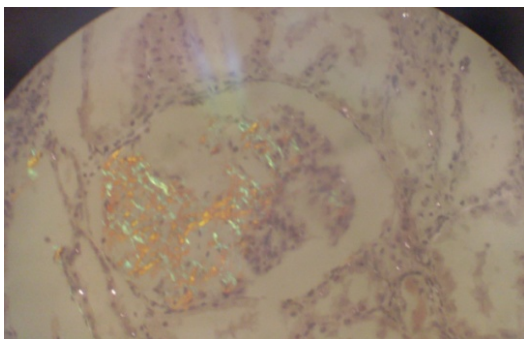


Fig. 2: The same figure (number 1), polarized microscopy×10

highest value in female sheep aged 1-2 year old (11/44) (25%). The most intense CR stained areas were observed in vicinity of the blood vessels (Fig. 5 and 6).

Vascular pattern of renal amyloidosis: In (4/44) animals (9.09%) CR positive areas was also detected in

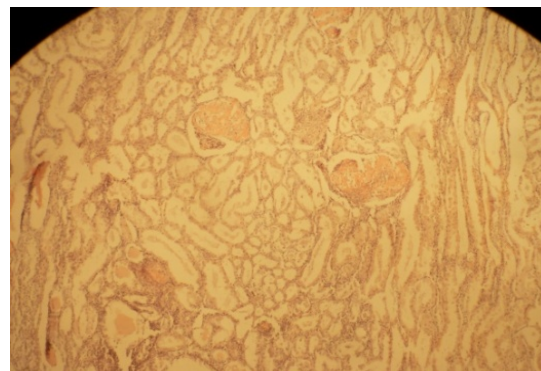


Fig. 4: Female sheep, 1-2 year old. Glomerular pattern of renal amyloidosis, Gglobal form (arrow). Note hyaline cast within the tubule (arrow head). Congo red staining. Light microscopy×4

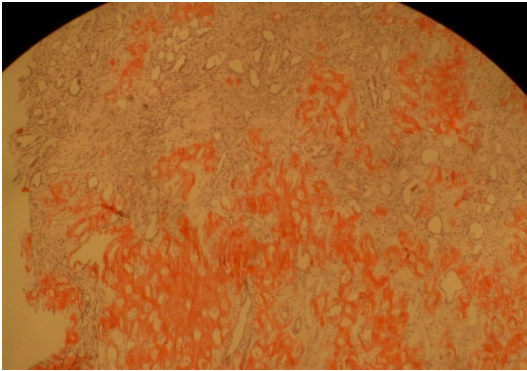


Fig. 5: Male sheep, 1-2 year old, renal medullary amyloidosis. Amyloidosis is observed as multifocal amyloid deposits. Congo red staining. Light microscopy×4




Fig. 6: The same figure (number -5), polarized microscopy×10

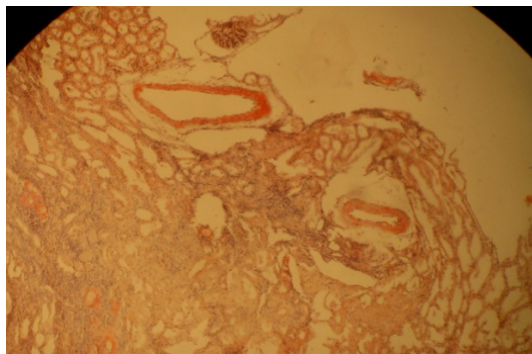


Fig. 7: Female sheep, >1 year old. Vascular pattern of renal amyloidosis. Amyloid deposits is seen in the wall of arteries, in both tunica intima and tunica media. Congo red staining. Light microscopy×4

arcuate arteries in both tunica intima and tunica media (Fig. 7 and 8); this lesion which was hard to detect by H&E staining was observed only in female animals above 1 year old with highest percentage in those between




Fig. 8: The same figure (number -7), polarized microscopy×4

1-2 year old. Regardless of different patterns of amyloid deposits, in all animals showing amyloidosis, variable degree of lesions including increased tubular diameter, epithelial hypertrophy, hyaline cast and occasionally hyaline granules were observed in proximal convoluted tubules (Fig. 3 and 4). These lesions were observed only in H&E stained sections.

DISCUSSION

In the present article, the detailed study on various patterns of renal amyloidosis in sheep is demonstrated, though the exact type of amyloid deposits (AA or AL) was not determined. For which the pretreatment of tissue sections with potassium permanganate is necessary.

In microscopic examination of renal tissue sections stained by CR and H&E techniques, renal medullary amyloidosis was the predominant feature of renal amyloidosis in sheep and to a lesser degree the glomerular and vascular patterns. This is in contrast to the previous findings reported in sheep and goat (Hadlow and Jellison, 1962), dogs and occasionally in cattle (Yoshida *et al.*, 2009). But this pattern of renal amyloidosis (RMA) was observed almost exclusively in the medulla of Dorcas gazelle (Jones, 1985) and other authors have also reported the same results most frequently in the renal medulla of cats (Linke *et al.*, 1984; Johnson and Jamison, 1984; Sato *et al.*, 1981) and cattle (Blunden and Smith, 1992; DiBartola *et al.*, 1989; Johnson and Jamison, 1984). In a previous study on renal amyloidosis in sheep, the amyloid deposits was initially localized to the glomerular capillary subendothelium but by progression of the disease, additional areas of the kidneys were also involved (Hadlow and Jellison, 1962).

In microscopic examination of the specimens with global form of glomerular amyloidosis, periglomerular infiltration of mononuclear cells were observed that was concordant with previous study on renal amyloidosis in sheep and goat (Hadlow and Jellison, 1962). This study reveals that the renal amyloidosis in domestic sheep

follows the same medullary pattern of renal amyloidosis in Dorcas gazelle, since, the medullary pattern of amyloidosis was the most prominent pattern.

In this study, the macroscopic lesions included miliary foci on capsular surface and radial striation only in cortical surface are attributed to resorptive and proteinaceous tubulo nephros is that affected the proximal convoluted tubules as the result of protein loss through impaired glomeruli due to amyloid deposition. This finding is in accordance (concordant) with previous findings in the same species and in bovine in renal amyloidosis (Blunden and Smith, 1992).

Susceptibility of female sheep than male sheep was another important finding in the present study. This finding is in contrast with the previous experimental study in which the preferential expression of reactive amyloidosis in male mice was revealed (Gruys, 1980).

Recent study, conducted by Japanese scientists has shown that dietary ingestion of amyloid fibrils which are found in AA amyloidosis and develops occasionally in aged cattle can enhance experimental murine AA amyloidosis. Thus, slaughtered aged cattle might be one dietary source exhibiting amyloid enhancing factor activity. The data obtained from our results suggest that food products made from aged sheep, particularly aged female sheep with the highest percentage of amyloidosis, may possess amyloid-enhancing potential (Bancroft and Gamble, 2008).

CONCLUSION

As a result, it is concluded that, the findings of the present study well demonstrated that the renal amyloidosis in domestic sheep follows the same medullary pattern of renal amyloidosis in Dorcas gazelle. To the best of our knowledge, this study seems to be the first comprehensive histopathologic study on renal amyloidosis in sheep from, Iran.

ACKNOWLEDGMENT

We thank the veterinarians and workers of the local slaughterhouse in Qom for their help in obtaining samples and Laboratory Technician of the Faculty of Veterinary Medicine, Department of Veterinary Pathology for his technical efforts.

REFERENCES

- Bancroft, J.D. and M. Gamble, 2008. Theory and Practice of Histological Techniques. 5th Edn., Churchill Livingstone Publisher, London, UK., Pages: 699.
- Blunden, A.S. and K.C. Smith, 1992. Generalised amyloidosis and acute liver haemorrhage in four cats. *J. Small Anim. Pract.*, 33: 566-570.
- Chew, D.J., S.P. DiBartola, J.T. Boyce and P.W. Gasper, 1982. Renal amyloidosis in related Abyssinian cats. *J. Am. Vet. Med. Assoc.*, 181: 139-142.
- Cotran, R.S., V. Kumar and T. Collins, 1999. Cellular Pathology I and II. In: Robbins Pathologic Basis of Disease. 6th Edn., W.B. Sanders Co., Philadelphia, pp: 1-49.
- Crawford, T.B., D.S. Adams, R.D. Sande, J.R. Gorham and J.B. Henson, 1980. The connective tissue component of the caprine arthritis-encephalitis syndrome. *Am. J. Pathol.*, 100: 443-454.
- DiBartola, S.P., M.J. Tarr, A.T. Parker, J.D. Powers and J.A. Pultz, 1989. Clinicopathologic findings in dogs with renal amyloidosis: 59 cases (1976-1986). *J. Am. Vet. Med. Assoc.*, 195: 358-364.
- Farnsworth, G.A. and S. Miller, 1985. An unusual morphologic form of hepatic amyloidosis in a goat. *Vet. Pathol.*, 22: 184-186.
- Gruys, E., 1977. Amyloidosis in the bovine kidney. *Vet. Sci. Commun.*, 1: 265-276.
- Hadlow, W.J. and W.L. Jellison, 1962. Amyloidosis in rocky mountain bighorn sheep. *J. Am. Vet. Med. Assoc.*, 141: 243-247.
- Hayden, D.W., K.H. Johnson, C.B. Wolf and P. Westermarck, 1988. AA amyloid-associated gastroenteropathy in a horse. *J. Comparative Pathol.*, 98: 195-204.
- Jakob, W., 1971. Spontaneous amyloidosis of mammals. *Vet. Pathol.*, 8: 292-306.
- Johnson, K.H., P. Westermarck, K. Sletten and T.D. O'Brien, 1996. Amyloid proteins and amyloidosis in domestic animals. *Amyloid*, 3: 270-289.
- Johnson, R. and K. Jamison, 1984. Amyloidosis in six dairy cows. *J. Am. Vet. Med. Assoc.*, 185: 1538-1543.
- Jones, D.B., 1985. Kidneys. In: Anderson's Pathology, Kissane, J.M. and W.A.D. Anderson (Ed.), Mosby Co, St. Louis, Missouri, pp: 742- 748.
- Jubb, K.V.F., P.C. Kennedy and N. Palmer, 2007. Pathology of Domestic Animals. Saunders Elsevier, Philadelphia,.
- Kingston, R.S., M.S. Shih and S.P. Snyder, 1982. Secondary amyloidosis in Dall's sheep. *J. Wildl. Dis.*, 18: 381-383.
- Kisilevsky, R., 1990. Heparan sulfate proteoglycans in amyloidogenesis: An epiphenomenon, a unique factor or the tip of a more fundamental process?. *Lab. Invest.*, 63: 589-591.
- Landman, W.J., N.H. Peperkamp, C.A. Koch, P.C. Tooten, P.A. Crauwels and E. Gruys, 1997. Induction of amyloid arthropathy in chickens. *Amyloid*, 4: 87-97.

- Linke, R.P., P.R. Hol and O. Geisel, 1986. Immunohistochemical identification of generalized AA-amyloidosis in a mountain gazelle (*Gazella gazelle*). *Vet. Pathol.*, 23: 63-67.
- Linke, R.P., P.R. Hol, E. Gruys, O. Geisel, W.B.J. Nathrath and G. Trautwein, 1984. Immunohistochemical identification and crossreactions of amyloid-a fibril protein in man and eleven other species. *J. Comp. Pathol.*, 94: 339-356.
- Lucke, V.M. and A.C. Hunt, 1965. Interstitial nephropathy and papillary necrosis in the domestic cat. *J. Pathol. Bacteriol.*, 89: 723-728.
- Mensua, C., L. Carrasco, M.J. Bautista, E. Biescas and A. Fernandez *et al.*, 2003. Pathology of AA amyloidosis in domestic sheep and goats. *Vet. Pathol.*, 40: 71-80.
- Monaghan, M., 1982. Renal amyloidosis in slaughtered cattle in Ireland. *Irish Vet. J.*, 36: 88-90.
- Munson, L., 1993. Diseases of captive cheetahs (*Acinonyx jubatus*): Results of the cheetah research council pathology survey, 1989-1992. *Zoo Biol.*, 12: 105-124.
- Murphy, C.L., M. Eulitz, R. Hrcic, K. Sletten and P. Westermark *et al.*, 2001. Chemical typing of amyloid protein contained in formalin-fixed paraffin-embedded biopsy specimens. *Am. J. Clin. Pathol.*, 116: 135-142.
- Nieto, J.M., S. Vazquez, M.I. Quiroga, M. Lopez-Pena, F. Guerrero and E. Gruys, 1995. Spontaneous AA-amyloidosis in mink (*Mustelavison*). Description of eight cases, one of which exhibited intracellular amyloid deposits in lymph node macrophages. *Eur. J. Vet. Pathol.*, 1: 99-103.
- Picken, M.M., 2001. The changing concepts of amyloid. *Arch. Pathol. Lab. Med.*, 125: 38-43.
- Rideout, B.A., R.J. Montali, R.S. Wallace, M. Bush, L.G. Phillips Jr, T.T. Antonovych and S.G. Sabnis, 1989. Renal medullary amyloidosis in Dorcas gazelles. *Vet. Pathol.*, 26: 129-135.
- Rings, M. and F.B. Garry, 1988. Amyloidosis associated with paratuberculosis in a sheep. *Comp. Food. Anim.*, 10: 381-385.
- Sato, A., T. Koga, M. Inoue and N. Goto, 1981. Pathological observations of amyloidosis in swans and other Anatidae. *Nihon Juigaku Zasshi. Jap. J. Vet. Sci.*, 43: 509-519.
- Schulze, C., M. Brugmann, M. Boer, H.P. Brandt, J. Pohlenz and R.P. Linke, 1998. Generalized AA-amyloidosis in Siberian tigers (*Panthera tigris altaica*) with predominant renal medullary amyloid deposition. *Vet. Pathol.*, 35: 70-74.
- Seifi, H.A., K. Karimi and A.R. Movassehgi, 1997. Renal amyloidosis in cattle: A case report in Iran. *J. Vet. Med. Seri. B.*, 44: 631-633.
- Shtrasburg, S., R. Gal, E. Gruys, S. Perl and B.M. Martin *et al.*, 2005. An ancillary tool for the diagnosis of amyloid a amyloidosis in a variety of domestic and wild animals. *Vet. Pathol.*, 42: 132-139.
- Tham, V.L. and C.M. Bunn, 1992. Amyloidosis in an Angora goat. *Aust. Vet. J.*, 69: 40-41.
- Westermark, P., K. Sletten and M. Eriksson, 1979. Morphologic and chemical variation of the kidney lesions in amyloidosis secondary to rheumatoid arthritis. *Lab. Inves. J. Tech. Methods Pathol.*, 41: 427-431.
- Yoshida, T., P. Zhang, X. Fu, K. Higuchi and S.I. Ikeda, 2009. Slaughtered aged cattle might be one dietary source exhibiting amyloid enhancing factor activity. *Amyloid*, 16: 25-31.
- Zschiesche, W. and W. Jakob, 1989. Pathology of animal amyloidoses. *Pharmacol. Ther.*, 41: 49-83.