

## Interrupted Aortic Arch Associated with Complex Congenital Heart Disease

Maryam Esmailzadeh, Alireza Moaref, Akbar and Shah Mohammadi  
Department of Echocardiography and Pediatric Cardiology,  
Shahid Rajaei Cardiovascular Medical Center,  
Iran University of Medical Sciences, Tehran, Iran

**Abstract:** Interrupted Aortic Arch (IAA) is a rare congenital malformation of the aortic arch that occurs in 3 per million live births. This anomaly is defined as a loss of luminal continuity between the ascending and descending portion of the aorta that entails a very poor prognosis without surgical treatment. In most cases IAA is associated with an intracardiac malformation such as VSD, PDA, bicuspid aortic valve, left ventricular outflow tract obstruction or aorto-pulmonary window. We report a 16 years old boy with IAA associated with double inlet left ventricle, aneurysmal dilatation of pulmonary artery, giant PDA and severe pulmonary hypertension. As our knowledge there is no previous report of IAA associated with complex congenital heart disease such as our case.

**Key words:** Interrupted Aortic Arch, Complex Congenital Heart disease, Echocardiography, Angiography

### CASE REPORT

A 16-year-old boy presented with cyanosis, dyspnea on exertion and easy fatigability since childhood. He had a previous history of cardiac catheterization 12 years ago because of cyanosis with a diagnosis of truncus arteriosus so patient left untreated. Physical examination on recent admission revealed central cyanosis, clubbing of fingers and toes, loud P2 in cardiac auscultation in association with mid systolic and holodiastolic murmur over chest. CXR showed cardiomegaly, increased pulmonary blood flow and pulmonary hypertension (Fig. 1).

Transthoracic echocardiography revealed double inlet single ventricle with LV morphology (Fig. 2) associated with levo-malposition of great vessels.

There was an aneurysmally dilated great vessel which was located centrally and defined as pulmonary artery with moderate to severe pulmonary insufficiency (Fig. 3) and severe pulmonary hypertension (mean PAP = 85 mmHg).

Aorta was small sized and anteriorly located. Patient underwent repeated cardiac catheterization and all above mentioned data were confirmed, also interrupted aortic arch (type A) was diagnosed; the descending aorta was supplied by pulmonary artery via a giant PDA (Fig. 4).

### DISCUSSION

Interrupted aortic arch (IAA) is a rare congenital malformation of the aortic arch that occurs in 3 per million

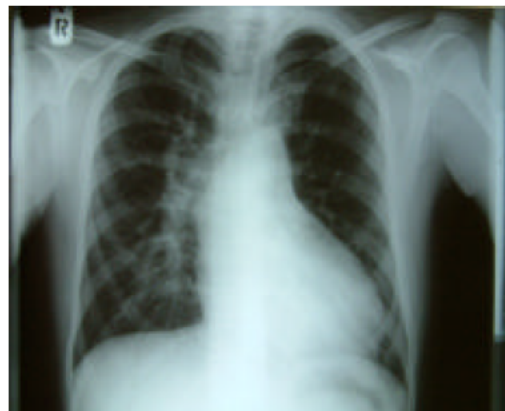

Fig. 1: CXR revealed cardiomegaly, increased pulmonary blood flow and pulmonary hypertension

live births.<sup>1</sup> This anomaly is defined as a loss of luminal continuity between the ascending and descending portions of the aorta<sup>2</sup> that entails a very poor prognosis without surgical treatment. In most cases, IAA is associated with an intracardiac malformation such as ventricular septal defect, patent ductus arteriosus, bicuspid aortic valve, left ventricular outflow tract obstruction, or aorto-pulmonary window. Interrupted aortic arch was initially described in 1778 by Steidele.<sup>3</sup> The 1st classification system, introduced by Celoria and Patton<sup>4</sup> in 1959, is still used almost universally. This system describes and classifies the site of aortic arch discontinuity, which may be distal to the left subclavian

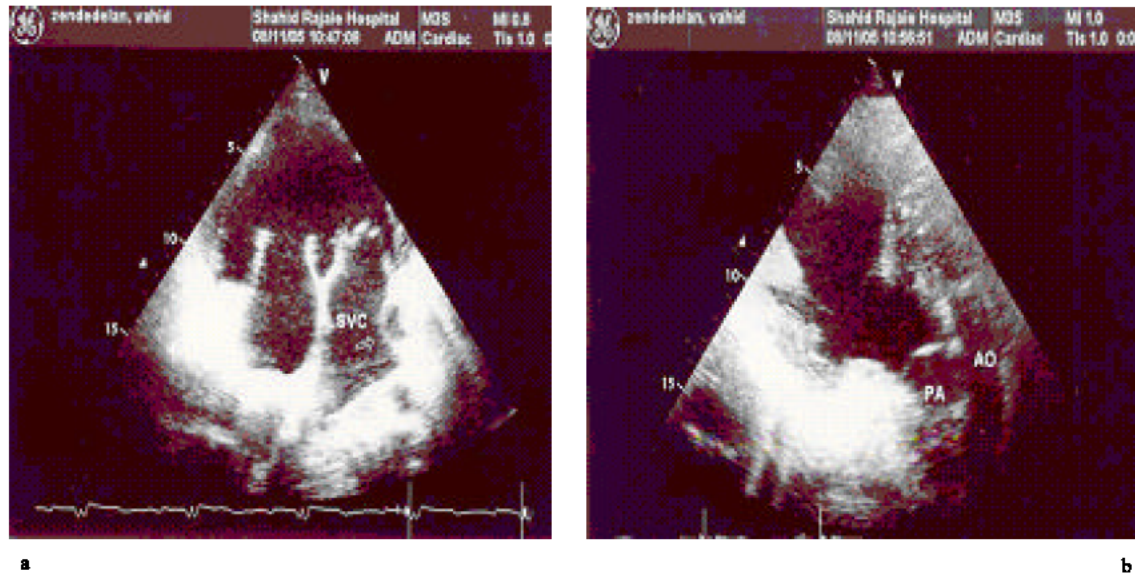


Fig. 2: Apical views showed double inlet single LV with dilated coronary sinus suggestive for persistent LSVC (a) and levomalposition of great arteries (b)

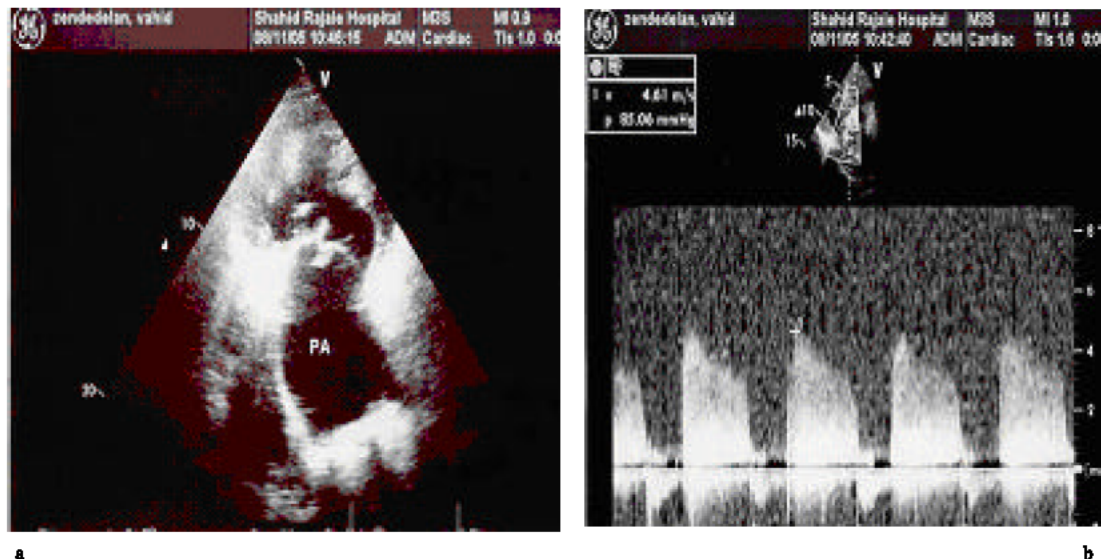


Fig. 3: 2D echocardiography revealed aneurysmal dilation of centrally located pulmonary artery (a). CW doppler showed significant pulmonary hypertension (b)

artery (type A); between the left carotid and left subclavian arteries (type B); or between the innominate and left carotid arteries (type C). The most common type is B (53%), followed by A (43%) and C (4%). In infants, its clinical presentation involves severe congestive heart failure; if the condition is left untreated, 90% of the affected infants die at a median age of 4 days.<sup>5</sup>In the few documented cases in adults, the presentation ranges from a lack of symptoms to limb swelling with differential blood

pressures in all extremities. Substantial collateral circulation must be present to maintain flow and enable survival. However, collateral vessels are subject to atrophy and atherosclerosis, which can lead to other challenging problems.<sup>6</sup>In adults, IAA is so rare that our review of the literature revealed only 12 cases. Nine of the patients underwent surgical repair.<sup>1,7-11</sup>IAA mostly diagnosed in early childhood due to congestive heart failure and differential cyanosis, but in our patient late

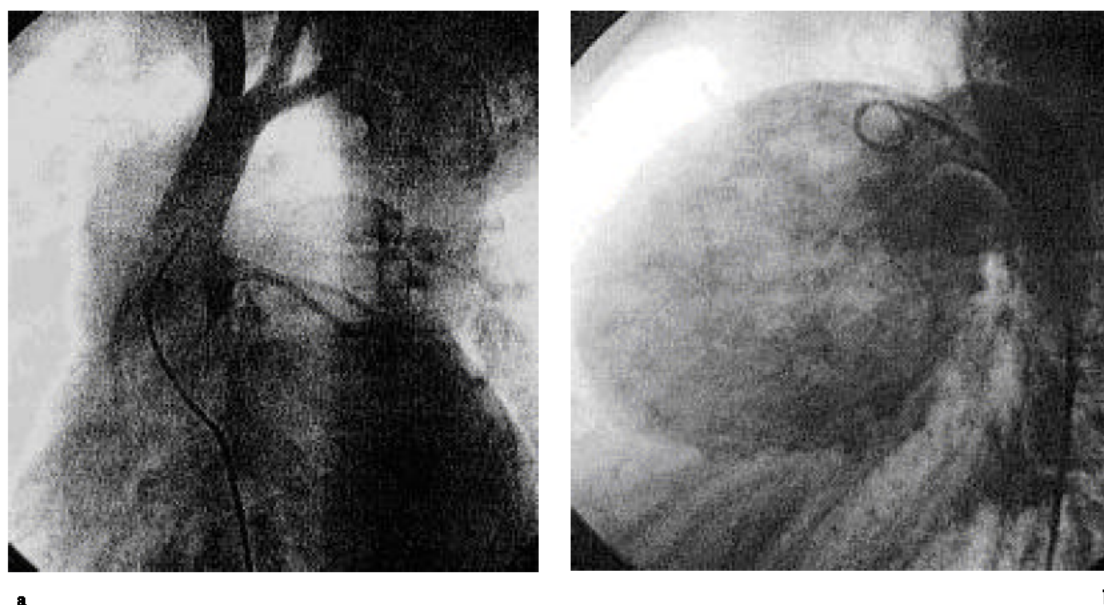


Fig. 4: Aortography (right) showed interruption of aortic arch after left subclavian artery take off (type A) and descending aorta is supplied by aneurysmally dilated pulmonary artery via a giant PDA (left)

diagnosis was secondary to double inlet LV with resultant mixing of saturated and unsaturated blood at the ventricular level and generalized cyanosis rather than differential cyanosis. Another problematic cause of misdiagnosis was very large central pulmonary artery which mimics truncus arteriosus. Patient was not candidate for any surgical intervention and heart and lung transplantation recommended.

#### REFERENCES

1. Canova, C.R., T. Carrel, P. Dubach, M. Turina and W.H. Reinhart, 1995. Interrupted aortic arch: Fortuitous diagnosis in a 72-year-old female patient with severe aortic insufficiency (in German). *Schweiz Med. Wochenschr*, 125: 26-30.
2. Backer, C.L. and C. Mavroudis, 2000. Congenital Heart Surgery Nomenclature and Database Project: Patent ductus arteriosus, coarctation of the aorta, interrupted aortic arch. *Ann. Thorac. Surg.*, 69: 298-307.
3. Steidele, R.J., 1778. *Samml Chir u Med Beob* (Vienna) 2: 114.
4. Celoria, G.C. and R.B. Patton, 1959. Congenital absence of the aortic arch. *Am. Heart J.*, 58: 407-413.
5. Collins-Nakai, R.L., M. Dick, L. Parisi-Buckley, D.C. Fyler and A.R. Castaneda, 1976. Interrupted aortic arch in infancy. *J. Pediatr.*, 88: 959-962.
6. Kreiger, K.H. and F.C. Spencer, 1985. Is paraplegia after repair of coarctation of the aorta due principally to distal hypotension during aortic cross-clamping? *Surgery*, 97: 2-7.
7. Prasad, S.V., S.K. Gupta, K.N. Reddy, J.S. Murthy, S.R. Gupta and H.S. Somnath, 1988. Isolated interrupted aortic arch in adult. *Ind. Heart J.* 40: 108-112.
8. Kauff, M.K., J. Bloch and H.A. Baltaxe, 1982. Complete interruption of the aortic arch in adults. *Radiol.*, 106: 53-57.
9. Todoric, M., N. Martinovic, J. Jablanov, M. Albreht, R. Aleksandrov and M. Prcovic, 1985. Interrupted aortic arch-case report of a patient successfully operated on in adulthood (in Serbo-Croatian (Roman)). *Acta Chir Jugosl*, 32: 201-206.
10. Burton, B.J.L., P. Kallis, C. Bishop, H. Swanton and C.W. Pattison, 1995. Aortic root replacement and extra-anatomic bypass for interrupted aortic arch in an adult. *Ann. Thorac. Surg.*, 60: 1400-1402.
11. Ogino, H., S. Miki, K. Matsubayashi, Y. Ueda and T. Nomoto, 1998. Two-stage repair for aortic regurgitation with interrupted aortic arch. *Ann. Thorac. Surg.*, 65: 1151-1153.