

Quantitative Evaluation of Arthroscopic Subacromial Decompression via MRI and its Consistency with Clinical Status in Patients

¹Ali Aydin, ¹Vahit Yildiz, ¹Omer Selim Yildirim, ¹Fatih Kalali, ¹Mesut Kilic and ²Aysenur Dostbil
¹Department of Orthopaedics and Traumatology, ²Department of Anaesthesiology and Reanimation,
Medical School Hospital, Ataturk University, 25240 Erzurum, Turkey

Abstract: The objective of the present study was to evaluate the relationship between subacromial distance measures before and after Arthroscopic Subacromial Decompression (ASD) using MRI and clinical status in patients with chronic impingement. About 44 patients with chronic impingements at stage 2 and 3 were evaluated using UCLA shoulder scale and the Constant-Murley shoulder assessment and their subacromial distances were measured using MRI before ASD. The average duration of follow-up was 30.48 months (12-49) after ASD. The same evaluations and measurements were obtained at the end of the follow-up period. The initial and final subacromial distances were different [9.23 (5-12) vs. 10.77 (6-14) mm, respectively]. The Constant-Murley shoulder assessment and UCLA shoulder scale scores also increased from 15.14-72.48 and from 8.09-30.89, respectively. The t-test confirmed statistical improvement in all these variables upon ASD ($p < 0.001$). In conclusion, clinical remission was associated with the subacromial distance elongation in patients with chronic impingement upon ASD.

Key words: Chronic impingement, subacromial distance, ASD, MRI, t-test, patients

INTRODUCTION

Patient age, physical activity level and functional status of the affected shoulder are considered when conservative treatment or surgical intervention is chosen in patients with chronic impingement. Recently, Arthroscopic Subacromial Decompression (ASD) has been employed successfully in the treatment of patients with chronic impingement who are unresponsive to conservative therapies. Thank to arthroscopy, success rate of acromioplasty in shoulder surgery (Atalar *et al.*, 2001). These surgical interventions are aimed to decompress subacromial region and consequently to prevent rotator cuff tension by relaxing it. The objective of this clinical study was to evaluate the relationship between subacromial distance measures before and after ASD using MRI and clinical status in patients with chronic impingement.

MATERIALS AND METHODS

About 24 males and 20 females with chronic impingement at the age of 48.55 (21-76) constituted the study population. Before ASD, shoulders of all patients were evaluated using MRI sagittal sections at 30° abduction when shoulder impingement was noted most (Fig. 1a). They were also evaluated using UCLA shoulder scale and the Constant-Murley shoulder assessment.

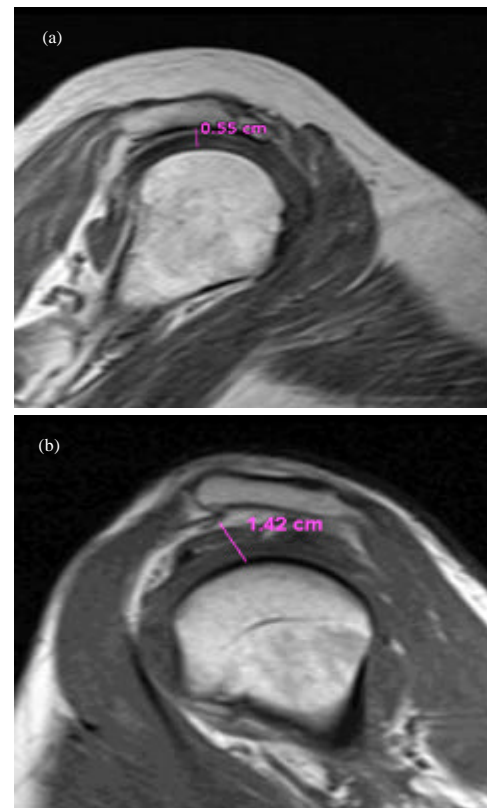


Fig. 1: The subacromial distance: a) before; b) after ASD

Corresponding Author: Ali Aydin, Department of Orthopaedics and Traumatology, Medical School Hospital,
Ataturk University, 25240 Erzurum, Turkey

Table 1: Changes in the subacromial distance and clinical status relative to ASD

Variables	Time relative to ASD		Positive rank	Negative rank	p-value
	Before	After			
The subacromial distance (mm ²)	9.23 (5-12)	10.77 (6-14)	36	0	<0.001
The Constant-Murley shoulder assessment	15.14 (2-52)	72.48 (2-90)	43	0	<0.001
The UCLA shoulder scale	8.09 (0-25)	30.89 (7-35)	44	0	<0.001

Following administration of interskalen block anesthesia, all patients were subjected to subacromial decompression and coracoacromial connective tissue resection arthroscopically at beach chair position. Two days after ASD, the patients were referred to physical therapy. The patients were followed 30.48 months (12-49) after ASD. At the end of the final check-up, MRI measurement (Fig. 1b) and evaluation tests were repeated. Data were subjected to descriptive statistics including normal distribution, frequency, mean and standard deviations. Data obtained before and after ASD were compared using t-test (SPSS, Version 16.0, Chicago, IL).

RESULTS AND DISCUSSION

Before ASD, the coracohumeral distances were 9.23 mm (5-12) and 10.36 mm (8-12) in affected and healthy shoulders, respectively ($p < 0.05$). The UCLA shoulder scale and the Constant-Murley shoulder assessment scores were 8.09 (0-25) and 15.14 (2-52), respectively. In the final check-up after ASD, the mean coracohumeral distance, the UCLA shoulder scale score and the Constant-Murley shoulder assessment score were 10.77 mm (6-14), 30.89 (7-35) and 72.48 (2-90), respectively. Relative to ASD, shoulder measurements and evaluation scores improved statistically ($p < 0.001$). Namely, the subacromial distance and clinical status improved significantly with ASD (Table 1).

Chronic impingement, resulting from rotator cuff entrapment in the subacromial region is characterized by shoulder pain and activity limitation. Neer (1972) defined impingement syndrome and proposed open acromioplasty for treatment in 1970. Later, acromioplasty and subacromial decompression were considered effective interventions for the chronic impingement cases in which conservative approaches failed (Neer, 1983).

In the present study, the subacromial distance in affected shoulder was shorter than healthy one before ASD (9.23 vs. 10.3 mm; $p < 0.05$). The subacromial distance, the Constant-Murley shoulder assessment score and the UCLA shoulder scale score increase significantly from 9.23-10.77 mm, 15.14-72.48 and 8.09-30.89, respectively at the end of averaging 30.48 months follow-up ($p < 0.001$). Subacromial bursa compression, effective decompression and regular exercise after ASD could also contribute to clinical remission.

Distance between acromion where is the insertion of supraspinatus tendon and caput humeri is 9-10 mm in the frontal position (Jobe, 1998). If this distance is < 6 mm, it is indication of subacromial impingement. In comparison of the subacromial distance in unaffected and affected shoulder, the distance was reported to range from 7-13 mm (Golding, 1962). Radiology and pathology studies ascertain that changes in the subacromial distance resulted from rotator cuff rupture (Cotton and Rideout, 1964). In fact, the subacromial distance in intact rotator sheet is 6-14 mm whereas, it is measured as 1-4 mm in full layer rotator muscle rupture (Cotton and Rideout, 1964).

In an early similar research, it was reported that the distance between acromion and caput humeri was 7-14 mm and < 5 mm distance could indicate rotator muscle rupture (Weiner and Macnab, 1970).

The degree of decompression is important in open or arthroscopic interventions. What causes continuation of complaints from lateral complete or radical acromionectomy and deltoid insufficiency (Bezer *et al.*, 2004). Atalar *et al.* (2001) suggested 33 mm decompression at 120° flexion. Lim *et al.* (2007) found no relationship between resection amount and clinical result but suggested that liberation of coracoacromial ligament and excision of subacromial bursa were more correlated with clinical remission.

CONCLUSION

In this study, the subacromial distance is affected shoulder was shorter than healthy one. ASD increased the subacromial distance and improved clinical evaluation tests scores in patients with chronic impingement.

REFERENCES

- Atalar, A.C., M. Demirhan, Y. Kocabey and Y. Akalin, 2001. Arthroscopic subacromial decompression: One-to seven-year results. *Acta Orthop. Traumatol. Turc.*, 35: 377-381.
- Bezer, M., N. Aydin, B. Erol, B. Kocaoglu and O. Guven, 2004. Late results of arthroscopic and open acromioplasty. *Acta Orthop. Traumatol. Turc.*, 38: 115-119.
- Cotton, R.E. and D.F. Rideout, 1964. Tears of the humeral rotator cuff: A radiological and pathological necropsy survey. *J. Bone Joint Surg.*, 46: 314-328.

- Golding, F.C., 1962. The shoulder-the forgotten joint. *Br. J. Radiol.*, 35: 149-158.
- Jobe, C.M., 1998. Gross Anatomy of the Shoulder. In: *The Shoulder*, Rockwood, C.A. Jr. and F.A. Matsen III (Eds.). 2nd Edn. Vol. 1, W.B. Saunders Company, Philadelphia, USA., pp: 34-97.
- Lim, K.K., H.C. Chang, J.L. Tan and B.K. Chan, 2007. Arthroscopic subacromial decompression for stage-2 impingement. *J. Orthop. Surg.*, 15: 197-200.
- Neer, C.S., 1972. Anterior acromioplasty for the chronic impingement syndrome in the shoulder: A preliminary report. *J. Bone Joint Surg.*, 54: 41-50.
- Neer, C.S., 1983. Impingement lesions. *Clin. Orthop.*, 173: 70-77.
- Weiner, D.S. and I. Macnab, 1970. Superior migration of the humeral head. A radiological aid in the diagnosis of the rotator cuff. *J. Bone Joint Surg.*, 52: 524-527.