

## Successful Non-operative Management of Grade IV Penetrating Renal Injury: A Case Report

Mohsen Kalhor, S. Ameneh Sabzi and Mehdi Molaei

Department of Surgery, Imam-Ali Hospital, Zahedan University of Medical Sciences, Zahedan, Iran

---

**Abstract:** Non-operative management of blunt renal injuries has become the standard of care. However, a routine surgical exploration remains the standard practice for high grade penetrating renal injuries. The concept of selective non-operative management for penetrating renal injuries has remained largely unexplored and operation is considered as the standard of care by most surgeons. We report, a case of stab wound with grade IV, renal injury who non-operatively managed successfully. We present a case of grade IV, renal injury after stab wound to left paraspinal area in a 26 years old Iranian male. The clinical and radiographic findings are presented along with the patient's conservative hospital course. We suggest that the management of high grades renal injury due to stab wound in hemodynamically stable patients can be non-operatively. But complete radiographic staging and close clinical observation are necessary.

**Key words:** Renal injury, trauma, conservative management, patients, hospitals, Iran

---

### INTRODUCTION

Trauma is defined as the morbid condition of body produced by external violence. Physicians with different specialities evaluate the trauma patients as a high level of expertise is required to prevent mortality and reduce morbidity (Demetriades *et al.*, 2006).

Renal injury occurs in approximately 1-5% of all traumas (Demetriades *et al.*, 2006; Baverstock *et al.*, 2001). As the kidney is the most commonly injured genitourinary and abdominal organ (Kristjansson and Pedersen, 1993), penetrating injuries tend to be more severe have a higher number of associated organ injuries and usually result in a higher nephrectomy rate (25-33%) than blunt traumas (Krieger *et al.*, 1984).

Renal trauma can be actually life threatening but the majority of renal injuries are mild and can be managed conservatively. Non-operative management of blunt renal injuries has become the standard of care for many years but a routine surgical exploration remains the standard practice for high grade penetrating renal injuries. Advances in the imaging and staging of trauma as well as in treatment strategies have decreased the need for surgical intervention and increased renal preservation.

We present a case of grade IV, renal injury due to paraspinal stab wound which managed non-operatively with complete radiologic staging and close clinical observation.

### MATERIALS AND METHODS

A 26 years old Iranian male referred to the emergency room of Khatam-ol-Anbia Hospital of Zahedan Medical University, complains of left flank pain after stab wound to left paraspinal area. The physical examination revealed a hemodynamically stable male not in respiratory distress with marked tenderness in the left flank area. The abdomen was soft without distension, tenderness or rebound tenderness. Both lungs have not any decreased breathing sounds. Site of stab wound was detected in left paraspinal area near L2 vertebral, 3 cm in length without active bleeding.

A Foley catheter was placed with drain of clear urine (without gross hematuria). Laboratory examination revealed a blood hemoglobin level about 12 g dL<sup>-1</sup> as well as a serum creatinine of 0.9 mg dL<sup>-1</sup> and blood urea nitrogen of 10 mg dL<sup>-1</sup> but urine analysis has microscopic hematuria. Computerized Tomography (CT) of the abdomen and pelvis with intravenous contrast demonstrated deep parenchymal laceration extending through renal cortex, medulla and collecting system to the hilum of left kidney with main vascular injury and contained hemorrhage and large hematoma that deviated left kidney from its normal position (Fig. 1). Because of the patient's hemodynamic stability, he was admitted to the surgery ward and treated conservatively with controlled fluid resuscitation, serial check of hemoglobin levels,

---

**Corresponding Author:** Mehdi Molaei, Department of Surgery, Imam-Ali Hospital, Zahedan University of Medical Sciences, Zahedan, Iran

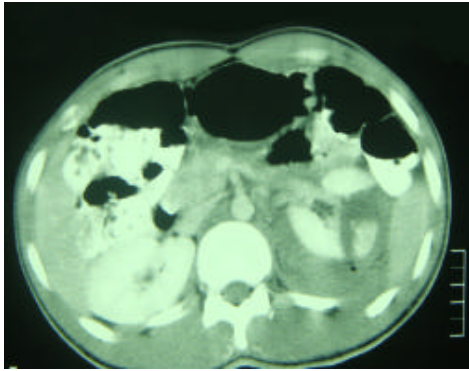


Fig. 1: Computerized tomography of the abdomen and pelvis with intravenous contrast. Deep parenchymal laceration extending through renal cortex, medulla and collecting system and hemorrhage and large hematoma that deviated left kidney from its normal position

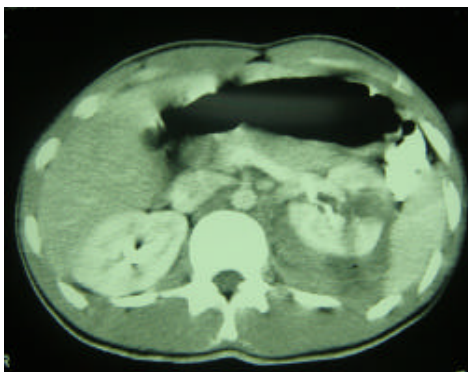


Fig. 2: Computerized tomography after 48 h, no evidence of expanding hematoma was founded

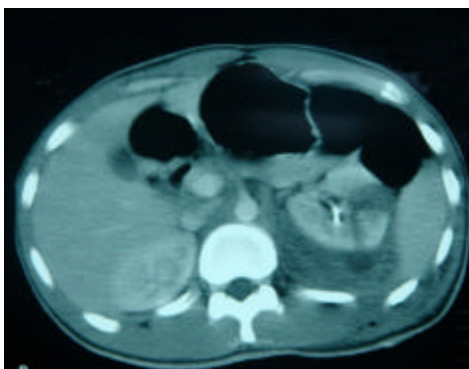


Fig. 3: Computerized tomography after 6 days, no evidence of expanding hematoma was founded

intravenous antibiotics and bed rest for 7 days. Two control computerized tomography after 48 h (Fig. 2) and

6 days (Fig. 3) was done and show no evidence of expanding hematoma and the extent of injury remained unchanged. The patient remained hemodynamically stable throughout his hospitalization with a serum creatinine and hemoglobin levels within normal limits and no need for packed red blood cells transfusion. The patient's microscopic hematuria resolved after 7 days then became ambulated with no further hematuria or anemia. Three months following the trauma, imaging revealed resolution of the retroperitoneal hematoma, return of the kidney to its anatomic position and acceptable renal parenchymal perfusion. At follow up, serum creatinine was 1.1 mg dL<sup>-1</sup>.

## RESULTS AND DISCUSSION

Selective non-operative management of blunt trauma to intra-abdominal solid organs has been established as the only acceptable standard of care (Santucci and Fisher, 2005). However, the role of non-operative management in penetrating solid organ injuries has not been widely explored and routine laparotomy is the usual practice (Demetriades *et al.*, 2006). Renal injuries are theoretically more amenable to non-operative management than other intra-abdominal solid organ injuries. The retroperitoneal position of the kidneys may contain bleeding and the rich blood supply may promote healing even after severe parenchymal injuries.

The success rate of non-operative management of blunt renal trauma, not involving the renal vessels has been reported as high as 95% (Nance *et al.*, 2004). Small series of successful non-operative management of patients with stab wounds to the kidneys were published as far back as 1985 (Carroll and McAninch, 1985). Routine exploration of the injured kidney may result in the unnecessary loss of the kidney.

The loss of a kidney, especially in the presence of other major associated injuries or septic complications may increase the risk of renal failure (Demetriades *et al.*, 2006). In the study by Demetriades *et al.* (2006), 14.9% of all patients with penetrating kidney injuries (or 50% of patients with isolated injuries) were successfully managed non-operatively. All grade I and II, renal injuries can be managed non-operatively. Recent studies support expectant treatment of grade III injuries (El Khader *et al.*, 1998). The majority of patients with grades IV and V renal injuries present with major associated injuries with a resultant higher rate of renal exploration (Santucci and McAninch, 2001). In one study by Bjurlin *et al.* (2010), non-operative management rate was 40.0% of grade I, 60% of grade II, 63.0% of grade III but just 5.9% of grade IV and 6.3% of grade V renal injuries. In the another study by Santucci *et al.* (2001), the need for surgery was grade

I = 0%, grade II = 15%, grade III = 76%, grade IV = 78% and grade V = 93% and for nephrectomy grade I = 0%, grade II = 0%, grade III = 3%, grade IV = 9% and grade V = 85%.

Absolute indications for surgery include life-threatening hemodynamic instability due to renal hemorrhage (McAninch *et al.*, 1991) and an expanding or pulsatile peritoneal hematoma identified at exploratory laparotomy which is usually a sign of grade V vascular injuries. Relative indications include persistent bleeding and suspected renal pelvis or ureteral injury.

The management of renal injuries with urinary extravasation or devitalized fragments has been controversial as some studies show increased rate of complications when they are managed non-operatively (Husmann and Morris, 1990).

In stable patients, supportive care with bed-rest, hydration and antibiotics is the preferred initial approach with complete staging to define the full extent of the injury that is associated with a lower rate of nephrectomy without any increase in the immediate or long-term morbidity and a low (5%) failure rate (Schmidlin *et al.*, 1997).

### CONCLUSION

We present a case of grade IV, renal injury following stab wound that managed non-operatively with success and suggest that management of these high grade injuries of kidney due to penetrating trauma can be non-operatively with complete radiographic staging and close clinical observation in properly selected patients.

### REFERENCES

Baverstock, R., R. Simons and M. McLoughlin, 2001. Severe blunt renal trauma: A 7-year retrospective review from a provincial trauma centre. *Can. J. Urol.*, 8: 1372-1376.

Bjurlin, M., E. Jong, S. Goble, J. Dohert and G. Morlotti, 2010. 1231 comparison of non-operative management with renorrhaphy and nephrectomy in penetrating renal injuries. *J. Urol.*, 183: 476-476.

Carroll, P.R. and J.W. McAninch, 1985. Operative indications in penetrating renal trauma. *J. Trauma*, 25: 587-593.

Demetriades, D., P. Hadjizacharia, C. Constantinou, C. Brown, K. Inaba, P. Rhee and A. Salim, 2006. Selective non-operative management of penetrating abdominal solid organ injuries. *Ann. Surg.*, 244: 620-628.

El Khader, K., A. Mhidia, J. Ziade, J.J. Patard, F. Guille and B. Lobel, 1998. Conservative treatment of stage III kidney injuries. *Acta Urol. Belg.*, 66: 25-28.

Husmann, D.A. and J.S. Morris, 1990. Attempted non-operative management of blunt renal lacerations extending through the corticomedullary junction: The short-term and long-term sequelae. *J. Urol.*, 143: 682-684.

Krieger, J.N., C.B. Algood, J.T. Mason, M.K. Copass and J.S. Ansell, 1984. Urological trauma in the pacific Northwest: Etiology, distribution, management and outcome. *J. Urol.*, 132: 70-73.

Kristjansson, A. and J. Pedersen, 1993. Management of blunt renal trauma. *Br. J. Urol.*, 72: 692-696.

McAninch, J.W., P.R. Carroll, P.W. Klosterman, C.M. Dixon and M.N. Greenblatt, 1991. Renal reconstruction after injury. *J. Urol.*, 145: 932-937.

Nance, M.L., N. Lutz, M.C. Carr, D.A. Canning and P.W. Stafford, 2004. Blunt renal injuries in children can be managed non-operatively: Outcome in a consecutive series of patients. *J. Trauma*, 57: 474-478.

Santucci, R.A. and J.M. McAninch, 2001. Grade IV renal injuries: Evaluation, treatment and outcome. *World J. Surg.*, 25: 1565-1572.

Santucci, R.A. and M.B. Fisher, 2005. The literature increasingly supports expectant (conservative) management of renal trauma-a systematic review. *J. Trauma*, 59: 493-503.

Santucci, R.A., J.W. McAninch, M. Safir, L.A. Mario, S. Service and M.R. Segal, 2001. Validation of the American Association for the surgery of trauma organ injury severity scale for the kidney. *J. Trauma*, 50: 195-200.

Schmidlin, F.R., S. Rohner, K. Hadaya, C.E. Iselin and B. Vermeulen *et al.*, 1997. The conservative treatment of major kidney injuries. *Ann. Urol.*, 31: 246-252.