

## Therapy of Non-Union of the Humeral Diaphysis-Comparison Between Locked and Conventional Implants

<sup>1</sup>B. Kienast, <sup>1</sup>M. Wurm, <sup>1</sup>K. Seide, <sup>2</sup>A. Paech <sup>1,2</sup>A.P. Schulz,

<sup>1,2</sup> C.H. Jürgens and <sup>3</sup>C. Queitsch

<sup>1</sup>Department of Traumatology, Orthopaedic and Reconstructive

Surgery, BG Trauma Centre Hamburg, Germany

<sup>2</sup> Department of Traumatology, Orthopaedic and Reconstructive Surgery

University of Schleswig-Holstein Campus Luebeck,

<sup>3</sup>Regio Kliniken, Krankenhaus Wedel

**Abstract:** In a retrospective study, we examined 43 patients with non-union of the humeral diaphys presenting in the time between January 1995 and January 2003. Fourteen patients had been treated with a 4.5 mm Low-Contact Dynamic Compression Plate (LCDCP) and autologous bone grafting; 29 patients were treated by an internal fixator with locked screws and also autologous bone grafting. The mean duration between trauma and operative treatment for the non-union was 18,3 month (5-58 month). An average of 1.5 previous operations had been performed before the final treatment. Primary nerve palsy was documented in 7 cases. All patients showed consolidation of the non-union at follow-up. In the LCDCP group two revisions in patients with osteoporosis were necessary, in the internal fixator group one re-osteosynthesis was required after a plate failure. The range of movement of shoulder and elbow increased rapidly after treatment of the pseudarthroses.

**Key words:** Humeral non-union, plate osteosynthesis, angular stability, locked implants

### INTRODUCTION

Approximately 3% of all fractures concern the humeral diaphysis (Bosch *et al.*, 1999). The humeral shaft heals the fastest and best of all long bones. Hence, closed fractures of the humeral diaphysis can often be treated conservatively with good results aesthetically and functionally (Blum *et al.*, 1998; Jupiter and Von Deck, 1998). Nevertheless, non-unions are still observed also after conservative therapy. The increasing enthusiasm in surgical therapy of the closed Humeral shaft fracture is the reason for the fact that pseudarthrosis is getting an increasing problem in the treatment of these fractures (Barquet *et al.*, 1989; Campbell, 1937). Pseudarthrosis occur in 2 to 3% of the cases after conservative treatment and in 6-16% after surgical treatment (Chen *et al.*, 2000; Jupiter and Von Deck, 1998; Lin *et al.*, 2000; Rosen, 1990; Siebert *et al.*, 1996). The main cause for the development of non-union after conservative therapy is the insufficient or missing contact of the main fragments. Particularly in transverse fractures or short oblique fractures it is often difficult to immobilise the main fragments for the time of the fracture healing (Bosch *et al.*, 1999; Jupiter and Von Deck, 1998). After conservative therapy mostly reactive, hypertrophic non-union occurs. Open reduction and

internal plate fixation usually leads to atrophic non-union (Bosch *et al.*, 1999; Campbell, 1937; Te Valde and Werken, 2001; Wenzl *et al.*, 2001). Extended soft tissue separation for the exposition of the fracture for anatomical reposition can be responsible for this. Other causes are insufficient reduction of the main fragments, osseous defects and unstable osteosynthesis. Rotational instability after intramedullary nailing osteosynthesis often leads to hypertrophic non-union (Bühren, 2000; Kuner *et al.*, 1995). Soft tissue interposition in the fracture gap can also lead to missing callus formation. A huge number of possibilities of treatment of the humeral shaft non-union are given in the literature (Barquet *et al.*, 1989; Blum *et al.*, 1998; Campbell, 1937; Healy *et al.*, 1987; Mc Kee *et al.*, 1996; Ring *et al.*, 1999). This retrospective study shows results for the operative treatment of humeral non-union with the use of LCDCP plate and angular stable internal fixator each with the use of autologous bone graft.

### MATERIALS AND METHODS

Between January 1995 and January 2003 we operated a total of 43 patients with non-union of humeral diaphysis fracture. Until September 1998 we used 4.5 mms Low-

Contact Compression Plate (LCDCP, Synthes, Bochum, Germany) for the stabilisation of the humeral diaphysis in 14 patients (Group A). From October 1998 to January 2003 we used an angular-stable internal fixator (Fig. 1, Ti-Fix, Litos, Hamburg, Germany) for a total of 29 patients (Fig. 2, Group B). The patient's data is shown in Table 1. Most frequent previous treatment in the examined groups was intramedullary nailing.

**Technique:** Twelve patients with proximal pseudarthrosis were operated in supine beach chair with arm table. We performed an anterolateral approach for these patients. The remaining 31 patients were suffering from non union localised in the medial part of the humeral shaft or distally. We chose a dorsal access in prone position with short arm table and 90° flexion of the elbow joint for these patients and the radial nerve was strictly exposed and tagged in the patients with dorsal instrumentation (Fig. 1). In all 43 patients the non-union region was carefully debrided and in all cases we used autologous bone graft after harvest from the anterior or dorsal pelvic spine. After surgery we used a Gilchrist bandage for few days until wound healing. Afterwards we began intensive physiotherapy without limitation of movement of the adjacent joints. We used a systemic antibiotic treatment with a cephalosporin of the 3-rd generation in all cases for about 3 days after surgery. In 3 cases the antibiotic treatment was extended to 7 days due to a positive swab.

**Complications:** In 3 patients complete radial nerve palsy occurred after surgery. All these cases were completely regressive after 3 months. Twice we observed loosening of the LCDCP plate in patients with severe osteoporosis. Both got re-osteosynthesis, one of them with the use of bone-cement. In the case of an obese patient an angular stable internal fixator broke 6 weeks postoperatively. We performed re-osteosynthesis with a new Ti-fix angular-stable plate fixator. In 3 patients the routine swab was positive. A contamination with staphylococcus epidermidis was proved in these 3 cases. Except the extended antibiotic treatment for 7 days no other measures were necessary. No deep wound infections occurred.

## RESULTS

We followed up 42 of 43 patients after a median time of 29.5 months (6-75 months). One patient died after cardiac infarction, X-rays 5 months after surgical therapy of the pseudarthrosis showed bony consolidation. Summarised bony consolidation was achieved in all patients. The three cases with postoperative radial nerve palsy were completely regressive after 3 months. Most patients had a remarkable restriction of Range of Movement (ROM) of the shoulder and elbow joint at the

affected side before therapy of the pseudarthrosis. Nevertheless, this restriction of ROM could be improved significantly after surgical stabilisation of the humerus (Table 2).

In Group A all 11 patients could return to work or were judged fit to work by GP. In Group B almost half of the patients were already retired. From the 15 remaining patients 13 patients got back to work 2 got retired early due to the accident.

## DISCUSSION

The therapy of non-union of the humeral diaphysis with plate osteosynthesis and cancellous bone transplantation has the biggest prospects of success. Already Campbell reported about a consolidation rate of about 94% in 50 patients with humeral shaft pseudarthrosis treated with plate osteosynthesis and cancellous bone transplantation. More actual studies proved similar success rates. Barquet *et al.* (1989) treated 25 humeral non-unions with a plate osteosynthesis and cancellous bone transplant. 96% of the cases showed bony consolidation after 3-8 months. Closed reduction and intramedullary nailing osteosynthesis without local revision of the pseudarthrosis lead to bony consolidation in only 17-70% of the cases (Jupiter and Von Deck, 1998). Only Lin *et al.* (2000) reported about successful treatment of the pseudarthrosis of the humeral shaft by means of intramedullary nailing in 39 of 41 cases. Nevertheless, with local debridement of the non-union and use of cancellous bone. In addition, the radial nerve was visualized in all cases. In our opinion also plate osteosynthesis would have been successful in these cases by a slight extension of the operative access. Problems in the shoulder and elbow area as they are known after anterograde or retrograde intramedullary nailing, could be avoided. Nevertheless, open reduction and internal plate fixation of the humeral pseudarthrosis is a demanding procedure due to the necessary exposure of the radial nerve and the risk of its injury. In the literature rates of the radial nerve injury vary between 5 and 8% (Bosch *et al.*, 1999; Mc Kee *et al.*, 1996; Ring *et al.*, 2000; Te Valde and Werken, 2000). This corresponds to our own experiences. There is almost always complete remission, if the continuity of the nerve is not interrupted (Healy *et al.*, 1987; Kuner *et al.*, 1995; Siebert *et al.*, 1996). Anyway every additional intervention leads to a clear rise of the danger of injury for the nerve. Therefore, surgical therapy of the humeral diaphysis should be guaranteed with only one intervention. For this reason we exclusively use titanium implants which do not have to be removed. In addition, we combine every internal osteosynthesis of the humeral shaft with a cancellous bone transplantation after harvesting from the dorsal pelvic spine, even in the treatment of hyperthrophic pseudarthrosis. We share this opinion

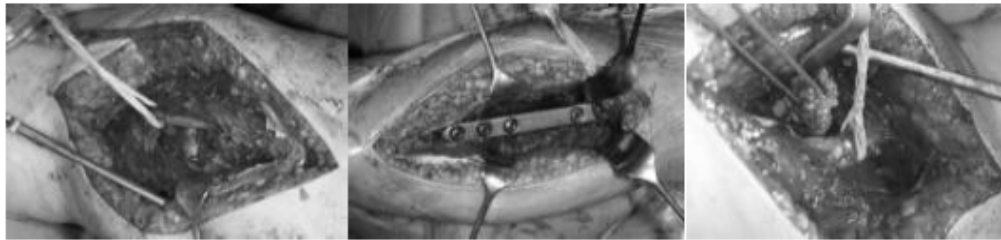
**Table 1: Patient data and pre-operations**

	Group A *	Group B
Treatment period	Jan.1 1995-Sept 30 1998	Oct. 1 1998-Jan.31 2003
Number of Patients	14(3f, 11m)	29(9f, 20 m)
Average age	38.9(18-76)	55.2(21-83)
Duration of Non-Union (Months)	9.3(5-26)	25.4(5-216)
Number of previous Operations	1.1(0-2)	1.7(0-4)
Primary Nerve lesion	1	6
Implants at prev. Surgery	None 3	None 2
(more than one possible)	Seidel Nail 2	Seidel Nail 3
	Ender Nail 6	Ender Nail 10
	Other Nails 1	Other Nails 8
	Plates 1	Plates 2
	Ext. Fixator 1	Ext. Fixator 3

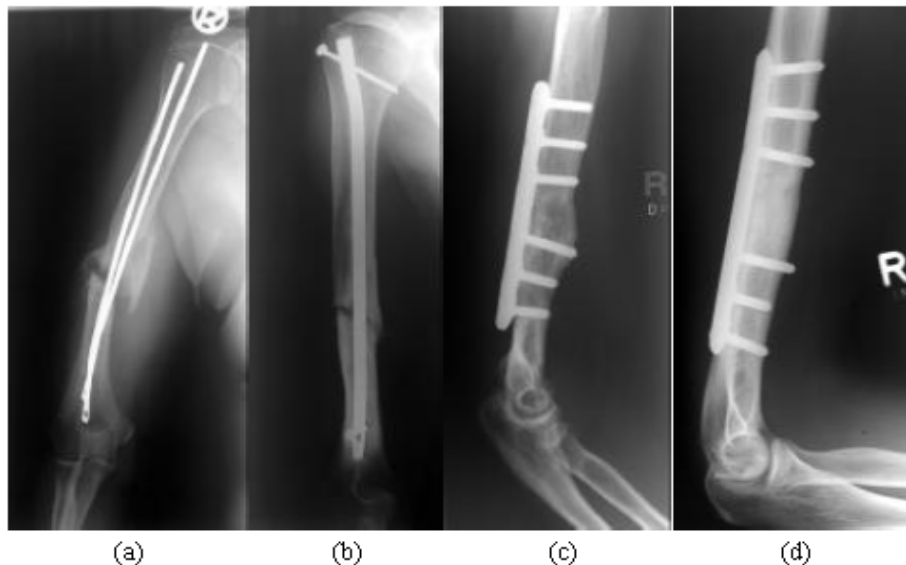\*Group A was treated with a 4.5mm L CDC-Plate and Group B with an angular stable internal fixator

**Table 2: Range of Movement (ROM) of the Shoulder and Elbow before and after bony consolidation of non-union (in Degree)**

	Group A(n=13)		Group B(n=29)	
	Preoperative	Postoperative	Preoperative	Postoperative
Abd. of shoulder	107(10-170)	165(80-180)	92(20-170)	149(80-180)
Flex. of shoulder	112(10-170)	165(80-180)	96.5(20-170)	153(90-180)
R.O.M. Elbow	119(60-140)	138(110-1140)	117(70-140)	138(115-150)



**Fig 1: Intraoperative Situs: Explored Pseudarthrosis (a), Stabilisation with angular stable internal fixator (b) and autologous bone graft (c)**



**Fig 2: Pre-and postoperative X-rays. Pseudarthrosis with Ender-Nails (a), intramedullary Nail (b). Stabilisation each with angular stable internal fixator(c+d)**

with several authors (Jupiter and Von Deck, 1998; McKee *et al.*, 1996; Lin *et al.*, 2000; Ring *et al.*, 1999, 2000). In our study, we compare results of the therapy of humeral non-unions with dynamic compression plate to those with an multidirectional angular stable internal plate fixator. Both implants can lead to bony consolidation,

although in the LCDCP group in 2 cases with extreme osteoporosis loosening of the plate occurred. The patients in the internal fixator group were significantly older, the number of the previous operations was higher and the duration of the existence of non-union was longer. Nevertheless, in this group only one implant failure occurred in a patient with severe obesity and missing compliance. Usually a longer lasting pseudarthrosis leads to a higher decrease of the osseous structures. The conventional compression plate is less dependable than the internal fixator when used for osteoporotic bone. This depends on the different biomechanical principles (Seide *et al.*, 1999; Wenzl *et al.*, 2001; Wolter *et al.*, 1999). Studies with the use of plastic bone from Seide *et al.* (1999) found a 3.3 times higher torsion stability for the angular stable internal fixator compared to the not angular stable LCDCP. In addition 6 screws (3 on every side of the non-union) provide sufficient stability when the internal fixator is used. (Rosen, 1990) recommends a 10 to 11-hole compression plate to allow the placement of at least 4-5 screws on every side of the pseudarthrosis. On average we used 9 hole compression plates with a length of 160 mm for our patients in Group A. 137 mm was the average length of the angular stable internal fixator we used for Group B, so by the use of angular stable implants smaller incisions could be made. In conclusion the results of locked vs. non-locked.

## CONCLUSION

Best possible conditions should be created for the therapy of the humeral non-unions. After our experiences with locked and non-locked implants, the theoretical advantages of angular stability match with the clinical results. Hence, we recommend the use of an angular stable internal fixator in combination with a cancellous bone graft for these demanding problems.

## REFERENCES

- Barquet, A., A. Fernandez, J. Uvizio and R. A. Masliak, 1989. Combined therapeutic protocol for aseptic nonunion of the humeral shaft. A report of 25 cases J. Trauma, 29: 95.
- Blum, J., P. M. Rommens, H. Janzig and H. S. Langendorf, 1998. Retrograde Nagelung von Humerusschaftfrakturen mit dem UHN. Eine internationale Multizentrische Studie. Unfallchirurgie, 101: 342-52.
- Bosch, U., M. Skutek, W. J. Kasperczyk and H. Tscherne, 1999. Diaphysäre Oberarmarthrosen-operative und konservative Behandlung. Chirurg, 70: 1202-8.
- Bühren, V., 2001. Kompressionsmarknagelung langer Röhrenknochen. Unfallchirurg, 103: 708-20.
- Campbell, W. C., 1937. Ununited fractures of the shaft of the humerus. ANN. Surg., 105: 35.
- Chen, C. M., F. Y. Chiu and W. H. LO, 2000. Treatment of acute closed humeral shaft fractures with Ender nails. Injury, 31: 683-5.
- Healy, W. L., G. M. White and C. A. Mick, 1987. Nonunion of the humeral shaft. Clin. Orthop., 219: 206-13.
- Jupiter, J. B. and M. Von Deck, 1998. Ununited humeral diaphysis. J. Shoulder Elbow Surg., 7: 644-53.
- Mc Kee, M. D., M. A. Miranda and B. L. Riemer, 1996. Management of humeral non-union after failure of locking intramedullary nails. J. Orthop. Trauma, 10: 492-9.
- Kuner, E. H., F. Bonnaire and D. J. Schaefer, 1998. Osteosynthese der Humerusschaftfraktur mit ORIF und DCP. Chirurg, 66: 1085-91.
- Lammens, J., G. Baudin and R. Driesen, 1998. Treatment of nonunion of the humerus using the Ilizarov external fixator. Clin. Orthop., 353: 223-30.
- Lin, J., S. M. Hou and Y. S. Hang, 2000. Treatment of humeral shaft delayed unions and non-unions with humeral locked nails. J. Traum, 48: 695-703.
- Ring, D., B. H. Perey and J. B. Jupiter, 1999. The functional outcome of operative treatment of ununited fractures of the humeral diaphysis in older patients. J. Bone Joint Surg. Br., 81: 177-90.
- Ring, D., J. B. Jupiter and J. Quintero, 2000. Atrophic united diaphyseal fractures of the humerus with bony defect. Treatment by wave-plate osteosynthesis. J. Bone Joint Surg. Br., 82: 867-71.
- Rosen, H., 1990. The treatment of nonunions and pseudarthroses of the humeral shaft. Orthop Clin. North Am., 21: 725-42.
- Seide, K., M. M. Morlock, U. Schümann and D. Wolter, 1999. Wirkprinzipien der winkelstabilen Schrauben-Platten-Verbindung bei Fixateur interne Osteosynthesen. Trauma Berufskh, 1: 320-5.
- Siebert, C. H., B. C. Heinz, H. R. Höfler and H. M. Hansis, 1996. Plattenosteosynthetische Versorgung von Humerusschaftfrakturen. Unfallchirurg, 99: 106-11.
- Te Velde, E. A. and C. Van der Werken, 2001. Plate osteosynthesis for pseudarthrosis of the humeral shaft. Injury, 32: 621-24.
- Wenzl, M. E., S. Fuchs, H. G. K. Schmidt and D. Wolter, 2001. Titan-Fixateur-interne-Systeme im Bereich der oberen Extremitäten. Trauma Berufskh, 3: 454-60.
- Wolter, D., U. Schümann and K. Seide, 1999. Universeller Titan-Fixateur interne. Entwicklungsgeschichte, Prinzip, Mechanik, Implantatgestaltung. Trauma Berufskh, 1: 307-19.