

## Hexaconazole Induced Changes in the Histological Architecture of Male and Female Reproductive Systems in Rats

P. Ravi Kumar, M. Kanniappan, L.N. Mathuram,  
S. Selvasubramanian, B. Murali Manohar and P. Sriram

Department of Pharmacology and Toxicology, Madras Veterinary College, 600-007 Chennai, India

**Abstract:** Hexaconazole is a triazole fungicide extensively used in agricultural and horticultural practices. The fungicidal action of triazoles is mainly attributed to their ability to inhibit cytochrome P450 dependent enzyme lanosterol 14  $\alpha$ -demethylase. Lanosterol 14  $\alpha$ -demethylase is necessary for the conversion of lanosterol to ergosterol which is an essential component of fungal cell membrane. Cytochromes P450 are ubiquitous heme containing proteins that are found through out the plant and animal kingdom and play a crucial role in the synthesis of steroidal hormones in mammals. Any interference in the synthesis of sex steroidal hormones will obviously affect the reproductive performance. Thus, hexaconazole was studied for its effect on histological architecture of male and female reproductive system in Wistar rats. Male rats were administered hexaconazole per os daily at 0.0, 27.5, 55.0 and 110.0 mg kg<sup>-1</sup> body weight for 30 and 60 days. Female rats were also given hexaconazole at the same dose level but for 30 and 73 days.

**Key words:** Triazoles, hexaconazole, histopathology, testis, ovary, endometrial glands

---

### INTRODUCTION

Triazoles are one of the promising groups of fungicides. They are broad spectrum systemic fungicides that offer both protective and curative effects (Bohmont, 1996). Triazoles inhibit the biosynthesis of ergosterol, an essential component of fungal cell membranes, via inhibition of the cytochrome P450 dependent enzyme lanosterol 14  $\alpha$ -demethylase. Lanosterol 14  $\alpha$ -demethylase is necessary for the conversion of lanosterol to ergosterol. At the molecular level, the N-4 nitrogen atom binds to the heme iron of cytochrome P450, there by inhibiting cytochrome activation and enzyme function (Van den Bossche *et al.*, 2000).

In addition, azoles may exhibit other direct effects on cell membrane fatty acids and can inhibit cytochrome P450 dependent enzymes of the fungal respiration chain (Uno *et al.*, 1982). The relative binding efficiency of the triazole antifungal agents to cytochrome P450 differs, resulting in variations in antifungal activity, toxicity of the agents and the relative likelihood of drug interactions with other cytochrome P450 metabolized drugs. Cytochromes P450 are ubiquitous heme containing proteins that are found through out the plant and animal kingdom and play a crucial role in the synthesis of steroidal hormones in mammals. Any interference in the

synthesis of sex steroidal hormones will obviously affect the reproductive performance. Hexaconazole is a triazole fungicide that is widely being used in agricultural and horticultural practices.

It has outstanding activity against a wide variety of diseases and its preventive, curative, systemic and antisporeulant properties provide a useful addition to the range of commercial fungicides (Vyas, 1993). The present study is aimed to know the pathological changes induced by hexaconazole in the histoarchitecture of male and female reproductive systems in rats.

### MATERIALS AND METHODS

**Male reproductive system:** Total 80 male Wistar strain rats (10-12 weeks old) were randomly assigned to IV equal groups. Group I served as control and received corn oil at 1 mL kg<sup>-1</sup> body weight per os daily. Group II through IV were administered hexaconazole (technical grade 92.5%, M/s Rallis India Limited, Agro Chemical Division, 400,703 Mumbai) suspension in corn oil daily at 27.5, 55.0 and 110.0 mg kg<sup>-1</sup> os<sup>-1</sup>, respectively.

Ten animals in each group received the treatment for 30 days and the remaining ten animals received the treatment for 60 days. After the end of the treatment, the animals were sacrificed under ether anesthesia to collect testis. Testis were fixed in Bouin's fluid for 24 h and later

were transferred to 70% alcohol until paraffin embedding and sectioning were done. The sections were stained with hematoxylin and eosin.

**Quantitative histopathology:** The slides were analyzed for number of seminiferous tubules per microscopic field, mean tubular diameter and percentage of damaged tubules.

Total number of seminiferous tubular cross sections and damaged tubules per microscopic field were counted in five fields per testis at a magnification of  $10\times 10$ . Testicular damage was assessed by determining the percentage of damaged tubules against the total tubules counted.

Twenty circular cross sectioned seminiferous tubules per testis were randomly selected and the tubular diameter was measured at a magnification of  $10\times 10$ .

**Female reproductive system:** Adult Wistar strain rats aged 90-110 days were randomly divided into IV groups each having 20 rats. Control rats in group I received corn oil at  $1\text{mL kg}^{-1}$  body weight per os daily and test rats in groups II-IV received hexaconazole (technical grade 92.5%, M/s Rallis India Limited, Agro Chemical Division, 400, 703 Mumbai) suspension in corn oil daily at 27.5, 55.0 and  $110.0\text{ mg kg}^{-1}\text{ os}^{-1}$ , respectively. Ten rats in each group were sacrificed on 30th day and remaining ten rats were sacrificed on 73rd day. The rats were sacrificed under ether anesthesia to collect ovaries, uterus and vagina.

These were initially fixed in Bouin's fluid for 24 h followed by fixation in 10% formalin. Sections were cut from paraffin embedded blocks and stained with hematoxylin and eosin for microscopic examination.

**Statistical analysis:** Data pertaining to quantitative changes in the testis of male rats were analysed by analysis of variance as described by Snedecor and Cochran (1968).

## RESULTS

### Male reproductive system

**Quantitative changes:** In rats exposed to the drug for 30 days, the number of seminiferous tubules observed per microscopic field was found significantly increased at medium and high dose levels (Table 1). This was accompanied by a significant decrease in the size of tubules (Table 1). In 60 days trial, also both medium and high doses caused a significant increase in the number of tubules observed per field with concomitant decline in the tubular diameter (Table 2).

In 30 days trial, low and medium doses did not produce a significant increase in the percentage of damaged tubules where as in high dose group the percentage of damaged tubules was significantly increased (Table 1). However in rats exposed for 60 days, medium dose also significantly increased the percentage of damaged tubules along with the high dose (Table 2).

**Qualitative changes:** While the low dose of hexaconazole did not cause any adverse effect on the histological architecture of the testis in rats, medium and high doses of the drug produced moderate to severe histopathological changes depending on the dose and duration of the trial.

The lesions observed in 30 days trial with high dose were degenerative changes in the gonadal cells, inter tubular edema (Fig. 1), impairment of spermatogenesis with accumulation of round cells within the lumen and mild Leydig cell hyperplasia. Medium dose of hexaconazole given for 60 days caused damage to testicular architecture though, it failed to produce any lesions in 30 days trial. High dose of hexaconazole given for 60 days resulted in severe damage to the testis. There were accumulations of large round cells and giant cells with in the lumen of seminiferous tubules, mild thickening of basement membrane and degenerative changes in gonadal epithelium (Fig. 2). Hypertrophy of Leydig cells was more marked in this group (Fig. 3) and in some places the Leydig cells showed degenerative and necrotic

Table 1: Effect of hexaconazole ( $30\text{ days os}^{-1}$ ) on seminiferous tubules in rat testis

Groups (mg/kg/day)	No. of tubules/microscopic field (mean $\pm$ SE)	Tubular diameter ( $\mu\text{m}$ ) (mean $\pm$ SE)	Damaged tubules (%) (mean $\pm$ SE)
I (0.0)	32.4 $\pm$ 2.5	240.5 $\pm$ 11.3	2.8 $\pm$ 0.2
II (27.5)	31.6 $\pm$ 1.9	242.8 $\pm$ 9.60	3.1 $\pm$ 0.7
III (55.0)	40.2 $\pm$ 3.1*	208.5 $\pm$ 7.20*	5.4 $\pm$ 0.4
IV (110.0)	46.7 $\pm$ 3.4**	180.4 $\pm$ 10.1**	28.3 $\pm$ 6.9**

Table 2: Effect of hexaconazole ( $60\text{ days os}^{-1}$ ) on seminiferous tubules in rat testis

Groups (mg/kg/day)	No. of tubules/microscopic field (mean $\pm$ SE)	Tubular diameter ( $\mu\text{m}$ ) (mean $\pm$ SE)	Damaged tubules (%) (mean $\pm$ SE)
I (0.0)	34.2 $\pm$ 3.1	236.2 $\pm$ 8.60	3.0 $\pm$ 0.4
II (27.5)	33.5 $\pm$ 2.7	239.4 $\pm$ 10.2	2.6 $\pm$ 0.2
III (55.0)	44.3 $\pm$ 5.3*	172.5 $\pm$ 10.7**	22.5 $\pm$ 1.5**
IV (110.0)	50.7 $\pm$ 4.4**	158.6 $\pm$ 12.1**	40.4 $\pm$ 3.2**

\* $p < 0.05$ ; \*\* $p < 0.01$

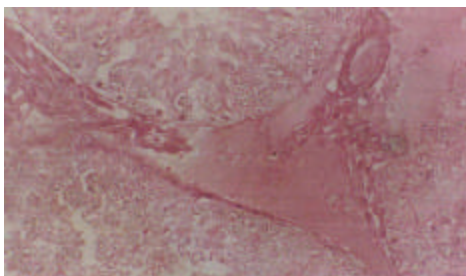


Fig. 1: Rat-hexaconazole (high dose 60 days). Testis showing intertubular edema H and E  $\times 360$

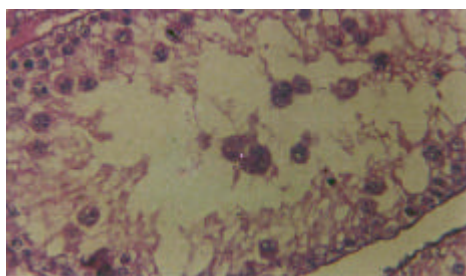


Fig. 2: Rat-hexaconazole (high dose 60 days). Testis showing degenerative changes in the gonadal epithelium with accumulation of giant cells within the lumen of seminiferous tubule H and E  $\times 360$

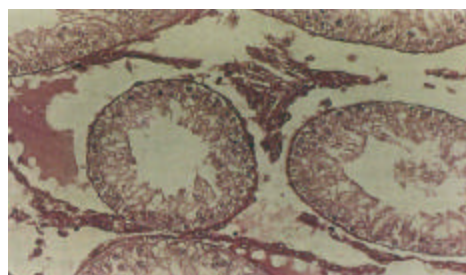


Fig. 3: Rat-hexaconazole (high dose 60 days). Testis showing absence of spermatogenesis and Leydig cell hypertrophy H and E  $\times 360$

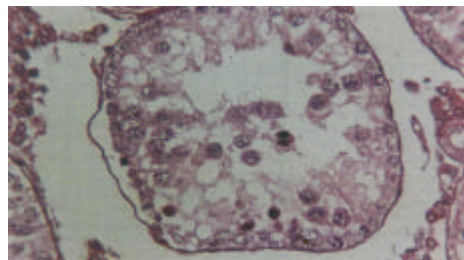


Fig. 4: Rat-hexaconazole (high dose 60 days). Testis showing complete absence of spermatogenesis and accumulation of cellular debris within the lumen H and E  $\times 300$

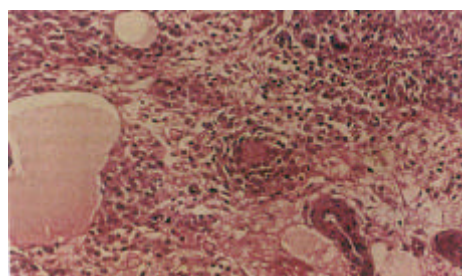


Fig. 5: Rat-hexaconazole (high dose 73 days). Ovary showing elongated glandular epithelial cells in the medulla H and E  $\times 360$

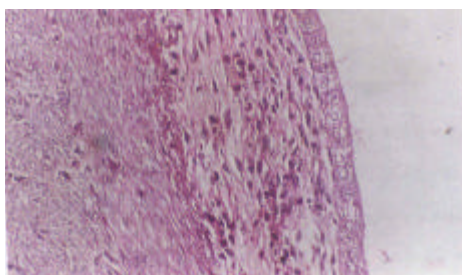


Fig. 6: Rat-hexaconazole (high dose 73 days). Uterus showing short columnar cells with basally placed nuclei with scanty glands H and E  $\times 360$

changes. Some seminiferous tubules showed complete absence of spermatogenesis with accumulation of cell debris in the lumen (Fig. 4).

**Female reproductive system:** It is evident based on the microscopic observation of the ovaries, uteri and vagina that exposure to hexaconazole for 30 days at the three dose levels had no effect on histological structure. However in the rats exposed to the drug for 73 days at high dose level, the ovaries showed mild changes in glandular epithelial cells which were elongated and spindle shaped with oval nuclei in the medulla (Fig. 5).

Compared to the changes in ovaries, the changes in uteri and vagina were more conspicuous. Uterus in the rats treated with hexaconazole for 73 days at medium dose showed scanty endometrial glands while in those treated with high dose the uterus showed small inactive epithelial cells lining the endometrium with large basally placed nuclei, atrophy of myometrium and absence of endometrial glands (Fig. 6).

In few cases, the endometrium revealed focal hyperplasia and squamous metaplasia (Fig. 7). Vagina showed marked atrophy of lining epithelium which appeared only 2-3 layered (Fig. 8).

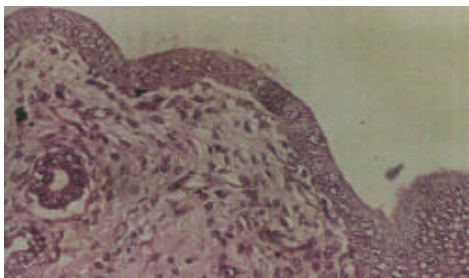


Fig. 7: Rat-hexaconazole (high dose 73 days). Uterus lining cells of endometrium showing focal hyperplasia and squamous metaplasia H and E  $\times 360$

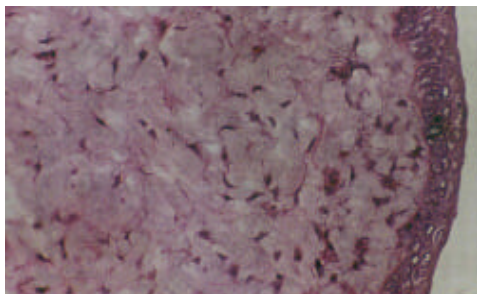


Fig. 8: Rat-hexaconazole (high dose 73 days). Vagina showing thinned out epithelium which is 2-3 layered H and E  $\times 360$

## DISCUSSION

Male rats were administered hexaconazole for 30 and 60 days. The 60 days maximum exposure period was chosen basing on 48 days as the period of spermatogenic cycle (Clermont and Harvey, 1967) and 9-14 days for sperm passage through the epididymus (Robb *et al.*, 1978). Christian (1997) also suggested that males be treated for 60 days, a full cycle of spermatogenesis. To know the effect of hexaconazole on testicular tissue, the tissue sections were subjected to quantitative and qualitative screening. In medium and high doses of hexaconazole, treated groups there was a significant increase in the number of tubules observed per field and a significant decrease in the tubular diameter.

These changes were more prominent in 60 days trial. The increase in seminiferous tubular number with concurrent decrease in tubular diameter indicated the atrophy of testis in treated groups. In addition to these atrophic changes, the testis also revealed more number of damaged tubules. However, medium dose of hexaconazole given for 30 days did not cause significant increase in the number of damaged tubules, though atrophic changes

were conspicuous. But the same dose of hexaconazole when given for 60 days resulted in appearance of significantly higher number of damaged tubules indicating the cumulative effect.

The qualitative changes consisted of degenerative lesions in gonadal cells, detachment of seminiferous epithelium with impaired spermatogenesis and hyperplasia of Leydig cells.

The intensity of these changes increased with dose and time of exposure. The degenerative changes might have resulted from the direct cytotoxic effect of hexaconazole on the seminiferous tubular cells. Leydig cell hyperplasia can be attributed to lowered circulating testosterone levels.

To maintain functional levels of testosterone, it is probable that the Leydig cells exhibited hyperplastic changes as a compensatory phenomenon. Triazole fungicides are reported to be potential inhibitors of cytochrome P450 enzymes (Colby *et al.*, 1995; Soltis and Colby, 1998; Vinggaard *et al.*, 2000) which in turn can adversely affect the testosterone synthesis. Hexaconazole has been reported to decrease serum testosterone levels in rats (Kumar *et al.*, 2011a).

Reproductive toxicity in females is less often studied because the toxicity is more difficult to detect and interpret. Reproductive function in the female is often a non-continuous cyclic process (Haschek and Rousseaux, 1998). In the present study, the female reproductive organs viz., ovary, uterus and vagina were collected from rats treated with hexaconazole for 30 or 73 days.

The present study formed part of reproductive toxicity evaluation of hexaconazole in female rats that were exposed to the drug for 73 days. The 73 days consisted of 30 days before mating, 1 day mating period, 21 days gestation period and 21 days lactation period. Histopathological examination of ovaries revealed no conspicuous changes except those in glandular cells at high dose level.

Uterus and vagina however, revealed atrophic changes. Recognition of atrophic ovary may be difficult in short term studies in rats because of continued follicular development.

However, ovarian interstitial glands, particularly those located in the medulla, offer valuable information about ovarian activity (Haschek and Rousseaux, 1998). Atrophy of uterus and vagina observed in the study can be considered as secondary to deficiency of ovarian steroidal hormones (Haschek and Rousseaux, 1998). Decrease in circulating estradiol and progesterone levels by the administration of substituted triazoles was reported by Middleton *et al.* (1986) and Milne *et al.* (1987), also reported decreased estradiol levels with another

substituted triazole. It is also reported that hexaconazole reduced, the circulating levels of estradiol and progesterone in rats (Kumar *et al.*, 2011b).

### CONCLUSION

The quantitative changes induced by hexaconazole in the, testis of male rats included a significant increase in the number of seminiferous tubules observed per microscopic field with significant decrease in the tubular diameter indicating testicular atrophy. The percentage of damaged tubules was also increased significantly. Prominent qualitative changes consisted of degenerative changes in gonadal cells, intertubular edema, impairment of spermatogenesis and Leydig cell hyperplasia. The severity of all the changes was dose and time dependent. In females, all the three dose levels given for 30 days had no effect on ovary, uterus and vagina. However, high dose given for 73 days resulted in certain changes that were more conspicuous in uterus and vagina than in ovary.

Ovaries showed mild changes in glandular epithelial cells which were elongated and spindle shaped with nuclei in the medulla. Uterus showed small inactive epithelial cells lining the endometrium, atrophy of myometrium and absence of endometrial glands. Vagina presented marked atrophy of lining epithelium which appeared only 2-3 layered.

### REFERENCES

- Bohmont, B.L., 1996. The Standard Pesticide User's Guide. 4th Edn., Prentice Hall, New Jersey, PP: 46-49.
- Christian, M.S., 1997. Reproductive and Developmental Toxicity Studies. In: Comprehensive Toxicology, Sipes, I.G., C.A. Mc Queen and A.J. Gondolfi (Eds.). Vol.II, Pergamon, Elsevier Science Ltd., Oxford, U.K., pp: 145-154.
- Clermont, R. and S.C. Harvey, 1967. Ciba Foundation Colloquia on Endocrinology. Churchill, London, pp: 173.
- Colby, H.D., B. Abbott, M. Cachovic, K.M. Debolt and B.A. Mico, 1995. Inactivation of adrenal cytochromes P450 by 1-aminobenzotriazole. Divergence of *in vivo* and *in vitro* actions. Biochem. Pharmacol., 49: 1057-1062.
- Haschek, W.M. and C.G. Rousseaux, 1998. Fundamentals of Toxicologic Pathology. Academic Press, USA., pp: 485-514.
- Kumar, P.R., M. Kanniappan, L.N. Mathuram, S. Selvasubramanian and P. Sriram, 2011a. Effect of hexaconazole on reproductive performance in female rats. Res. Opinions Anim. Vet. Sci., 1: 74-77.
- Kumar, P.R., M. Kanniappan, L.N. Mathuram, S. Selvasubramanian and P. Sriram, 2011b. Alterations in gonado somatic index, seminogram and testosterone profiles in rats treated with hexaconazole. Res. Opinions Anim. Vet. Sci., 1: 78-82.
- Middleton, M.C., C.M. Milne, S. Moreland and R.L. Hasmall, 1986. Ovulation in rats is delayed a substituted triazole. Toxicol. Applied Pharmacol., 83: 230-239.
- Milne, C.M., R.L. Hasmall, A. Russel, S.C. Watson, Z. Vaughan and M.C. Middleton, 1987. Reduced estradiol production by a substituted triazole results in delayed ovulation in rats. Toxicol. Applied Pharmacol., 90: 427-435.
- Robb, G.W., P.P. Amann and G.J. Killian, 1978. Daily sperm production and epididymal sperm reserves of pubertal and adult rats. J. Reprod. Fertil., 54: 103-107.
- Snedecor, G.W. and W.G. Cochran, 1968. Statistical Methods. Oxford and IBH Publishing Company Pvt. Ltd., Calcutta.
- Soltis, M. and H.D. Colby, 1998. Inhibition of testicular steroidal metabolism by administration of 1-aminobenz triazole to rats. Pharmacology, 56: 51-56.
- Uno, J., M.L. Shigematsu and T. Arai, 1982. Primary site of action of ketoconazole on *Candida albicans*. Antimicrobial Agents Chemotherapeutics, 21: 912-918.
- Van den Bossche, H.D., D. Bellens, W. Cools, J. Gorrens and P. Marichal *et al.*, 2000. Screening of selected pesticides of inhibition of CYP19 aromatase activity *in vitro*. Toxicol. *In vitro*, 14: 227-234.
- Vinggaard, A.M., C. Hnida, V. Breinholt and J.C. Larsen, 2000. Screening of selected pesticides for inhibition of CYP19 aromatase activity *in vitro*. J. Toxicol. *In Vitro*, 14: 227-234.
- Vyas, S.C., 1993. Hand Book of Systemic Fungicides. Tata McGraw Hill Publishing Co. Ltd., New York.