

## Heterotopic Pregnancy in Spontaneous Conception: A Case Report

<sup>1</sup>Maasoumeh Mirzamoradi, <sup>2</sup>Zahra Heidar and <sup>3</sup>Maasoumeh Saleh

<sup>1</sup>Department of Perinatology,

<sup>2</sup>Department of Infertility, Mahdیه Hospital,  
Shahid Beheshti University of Medical Sciences, Tehran, Iran

<sup>3</sup>Department of Gynecology and Obstetric,  
Shahid Beheshti University of Medical Sciences, Tehran, Iran

---

**Abstract:** Heterotopic pregnancy is defined as coexistence of intrauterine and ectopic pregnancy at the same time. It although common with assisted reproductive techniques is very rare in natural conception. Ruptured ectopic pregnancy carries a significant maternal mortality and morbidity, so timely diagnosis and management is crucial. We report a case of heterotopic pregnancy in a 26 year old woman presented with acute abdomen. Immediate surgical intervention was done with diagnosis of ruptured ectopic pregnancy. This case suggests that intrauterine gestational sac may be a false reassurance, especially in women presenting a pelvic pain. Heterotopic pregnancy can occur in the absence of any predisposing risk factors. Early diagnosis is necessary for the best maternal and intrauterine fetus outcome, hence every physician should be aware of the possibility of heterotopic pregnancy.

**Key words:** Heterotopic, ectopicpregnancy, natural conception, diagnosis, maternal

---

### INTRODUCTION

Heterotopic pregnancy is a condition in which pregnancies occur at two different implantation sites, most often combination of intrauterine and ectopic pregnancies, rather than two ectopic pregnancies. In a review of 66 heterotopic pregnancies by Reece *et al.* (1983) 93.9% of extrauterine sites were tubal. It was first reported in the year 1708 as an autopsy finding (Khedili *et al.*, 2012).

Ectopic pregnancy remains an important cause of maternal mortality worldwide (Bushra *et al.*, 2013) and about 5% of women with ectopic pregnancy present in haemorrhagic shock. Heterotopic pregnancy occurs 1 in 30,000 pregnancies (Bright and Gaupp, 1990). Although, heterotopic pregnancy is a rare event in spontaneous conception, incidence is increasing due to assisted reproductive techniques.

Similar to tubal ectopic pregnancies, the most common complaint in heterotopic pregnancy is lower abdominal pain, occurring in 81.8% of patients (Bright and Gaupp, 1990) and most cases present in emergency room. It is a life-threatening condition that can be easily missed. Diagnosis is difficult. Trans vaginal sonography detected only 50% of heterotopic pregnancies and serial levels of B-HCG are not

helpful. Clinical suspicion is the key to identifying women who need prompt and careful evaluation. The presence of an intrauterine pregnancy does not exclude the heterotopic pregnancy, especially in women presenting a pelvic pain. We report a case of heterotopic pregnancy in a natural conception.

### MATERIALS AND METHODS

**Case presentation:** A 26 years old Iranian woman, gravida 2 with a 5 year old child resulting from cesarean section was brought to our emergency room in the gynecology and obstetrics department with severe lower abdominal pain, nausea and vomiting for the last 10 h. It was a spontaneous conception. She reported 10 weeks amenorrhea and had a transvaginal sonography showing an alive intrauterine fetus and normal adnexa for 3 days ago. She did not have any pelvic pain during this time. On examination, she was pale with a pulse rate of 110 per min and blood pressure of 90/60 mmHg. Abdominal examination revealed diffuse, lower abdominal tenderness and guarding. Pelvic examination revealed an enlarged uterus corresponding to 10 weeks of pregnancy and a palpable mass in left adnexa. Laboratory tests showed Hgb:8.7. A transvaginal sonography showed an alive

fetus (10 weeks) in the uterine cavity and a 4730 mm hypoechoic mass in left adnexa with severe free fluid in abdominopelvic cavity. Due to acute abdomen and instable hemodynamics, she undergo an emergency exploration laparotomy after initial resuscitation with intravenous colloids. Laparotomy confirmed the rupture of left tubal pregnancy on ampulae and found 1500 cc fresh blood and 500cc clot in peritoneum. After peritoneal

lavage, left salpingectomy was done and intrauterine pregnancy preserved. The patient was transfused with two units of packed cell during surgery and after a good postoperative period was discharged. Pathologist reported tubal contents as ectopic pregnancy. She was followed up until delivery on term by cesarean delivery, resulting a normal male fetus with birth weight of 3270 g (Fig. 1).

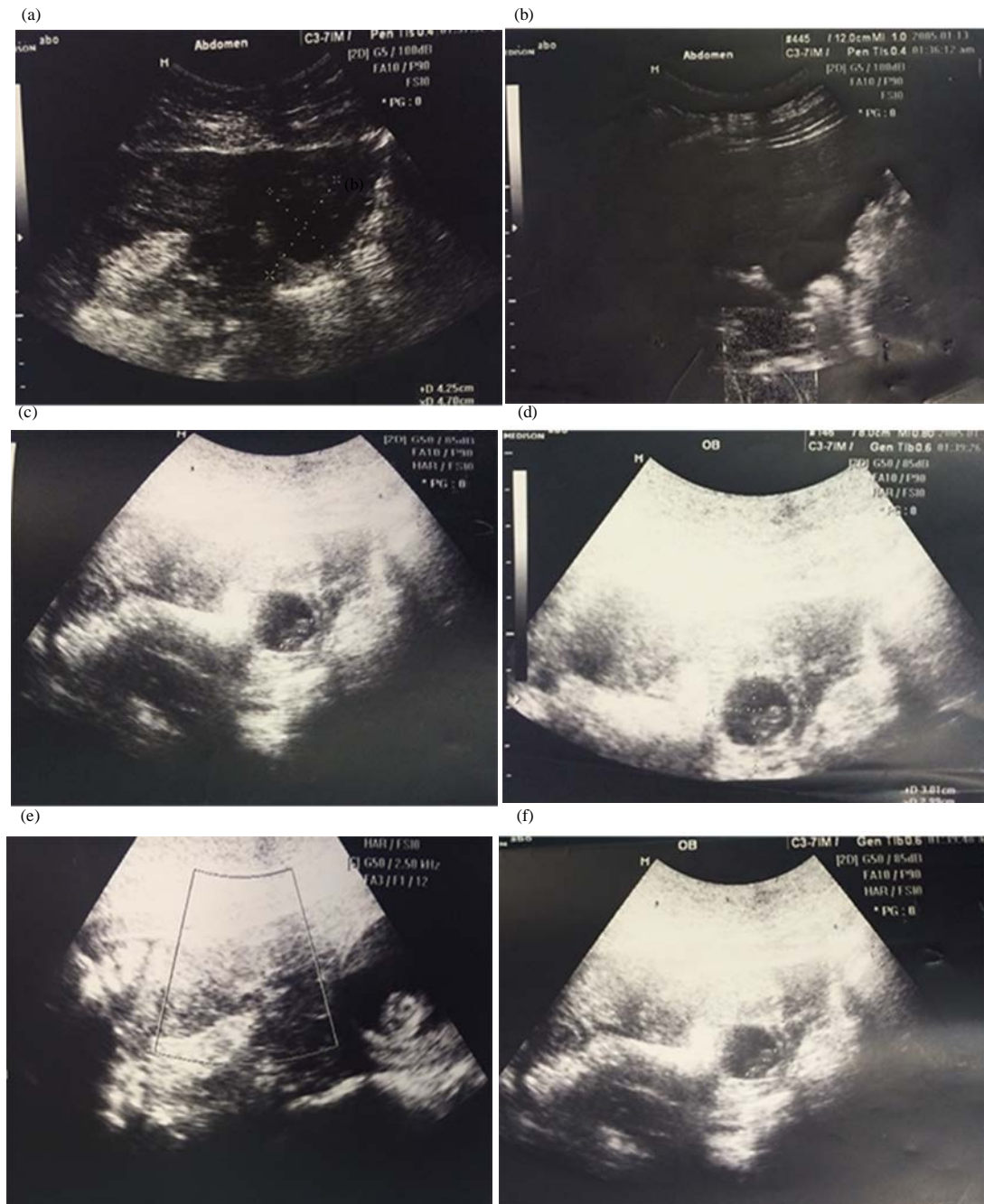


Fig. 1: Continue

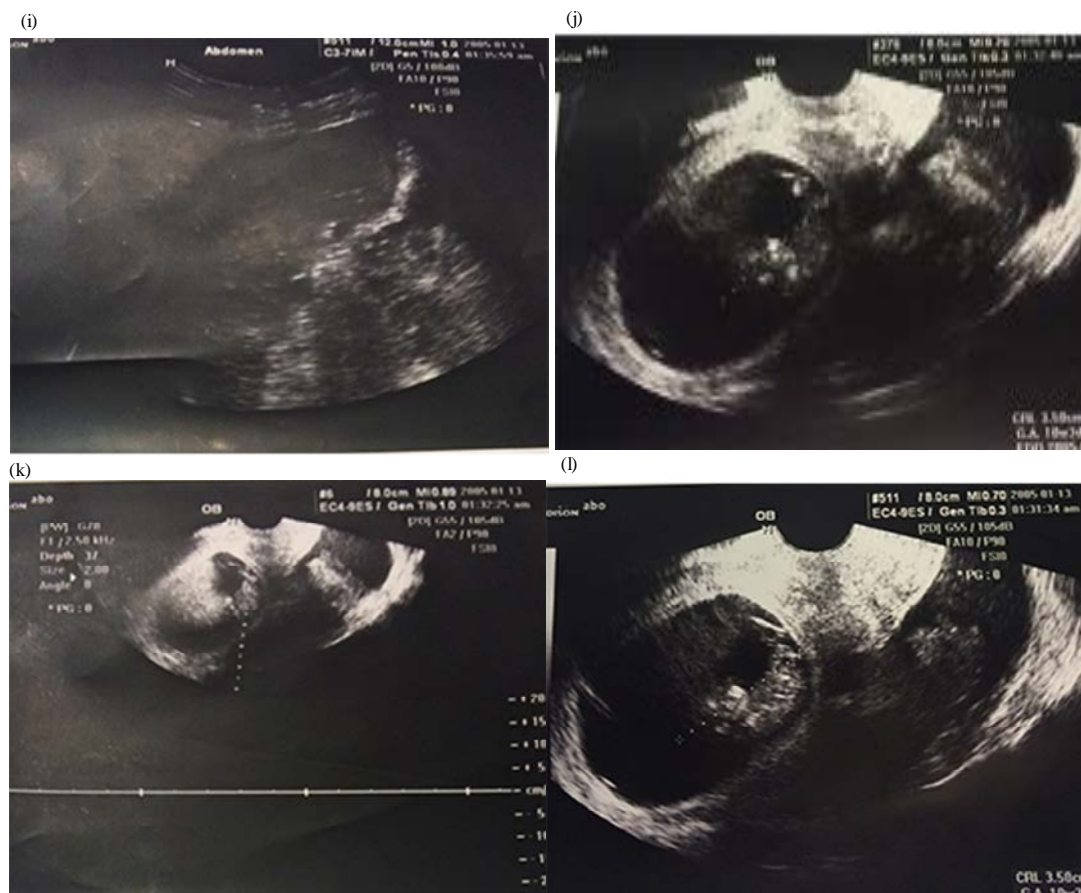


Fig. 1: The sonographic images of pregnant women

## RESULTS AND DISCUSSION

Ectopic pregnancies are serious complications of pregnancy, especially when they are diagnosed after rupture (Baafuor *et al.*, 2013). Ectopic pregnancy remains responsible for 6% of maternal deaths which mainly occur after an acute initial presentation (Anonymous, 2014). The exact cause of ectopic pregnancy may not be known. Women with history of pelvic infection, abdominal surgery, previous ectopic pregnancy, IVF pregnancy and who have IUD as a contraceptive method are at greater risk of ectopic pregnancy. Heterotopic pregnancy can occur in the absence of any predisposing risk factors. The patient in this report, only had, previous cesarean section as a risk factor. Heterotopic pregnancies are becoming more common following assisted conception techniques for subfertility (Raziel *et al.*, 1997) however, spontaneous heterotopic pregnancies are quite rare (Jerrad *et al.*, 1992). In our case, pregnancy was resulted from a natural conception.

The most common location of ectopic gestation in heterotopic pregnancy is the fallopian tube. Heterotopic pregnancy can have various presentations. The most

common symptom is abdominal pain. In this case ectopic pregnancy was in fallopian tube and she presented with acute abdomen. Diagnosis of ectopic pregnancy is difficult due to:

- Absence of clinical symptoms
- The identification of an intrauterine pregnancy can divert attention from the possibility of a concurrent ectopic pregnancy in the absence of any clinical sign of the ectopic pregnancy (Khediri *et al.*, 2012)
- The sensitivity of transvaginal sonography in diagnosing heterotopic pregnancy is only 56% at 5-6 weeks (Dundar *et al.*, 2006)
- B-HCG levels are not helpful due to coexistence of intrauterine pregnancy

Differential diagnosis of heterotopic pregnancy are:

- Intrauterine gestation and hemorrhagic corpus luteum
- Bicornuate uterus with gestation in both cavities
- Other causes of acute abdomen

Treatment options include:

- Injection of potassium chloride or prostaglandin in to the gestational sac in the fallopian tube
- Surgery (laparoscopy or laparotomy). Laparotomy is only chosen when the patient has instable hemodynamics

Khediri *et al.* (2012) reported three cases of heterotopic pregnancies after a natural conception, all have presented firstly an acute abdominal pain and managed surgically. Two of them had a TVS examination prior to the rupture of the tubal pregnancy which overlooked the diagnosis. Diagnosis was between 6 and 8 weeks (the most common period).

Jahan *et al.* (2011) reported a case of heterotopic pregnancy who presented abdominal pain and vaginal bleeding and managed as an early pregnancy loss due to intrauterine pregnancy showed in transvaginal sonography but after discharging, she presented acute abdomen and instable hemodynamics and laparotomy revealed an ruptured ectopic pregnancy. This report showed, diagnosis of heterotopic pregnancy prior to rupture is an arduous task even with the availability of many new investigative methods. A suspicion is necessary in early pregnancy and abdominal pain.

Dzenita *et al.* (2011) reported a case of heterotopic pregnancy in natural conception and without any predisposing factor who presented acute abdomen and laparotomy revealed ruptured ectopic pregnancy. It showed, heterotopic pregnancy can occur in the absence of any risk factors and the detection of intrauterine pregnancy does not exclude the possibility of ectopic pregnancy at the same time.

## CONCLUSION

A high suspicion to heterotopic pregnancy is necessary in patients in which ultrasound findings are consistent with intrauterine gestation but they presented

abdominal or pelvic pain and/or have free fluid in pelvis. A heterotopic pregnancy is rare but fatal, so timely diagnosis and management is crucial.

## REFERENCES

- Anonymous, 2014. Clinical practice guideline, The diagnosis and management of ectopic pregnancy. Institute of Obstet. Gynecol., 1 (33): 1-24.
- Bushra, K. *et al.*, 2013. A 10 year review of 255 cases of ectopic pregnancy. J. Androl. Gynecol., 1 (2): 1-4.
- Bright, D.A. and F.B. Gaupp, 1990. Heterotopic pregnancy: A reevaluation. J. Am. Board Fam Pract, 3: 125-128.
- Baafuor, K.O. *et al.*, 2013. Ectopic pregnancy are fair-colored women at increased risk? J. Hebet Open Access, 1: 1-4.
- Dzenita, L. *et al.*, 2011. Heterotopic pregnancy in natural conception-our initial experience: case report. Acta Clin. Croat, 50: 249-252.
- Dundar, O. *et al.*, 2006. Heterotopic pregnancy: tubal ectopic pregnancy and monochorionic monoamniotic twin pregnancy: A case report. J. Perinat., 14: 96-100.
- Jerrad, D. *et al.*, 1992. Unsuspected heterotopic pregnancy in a woman without risk factors. Am J. Emerg. Med., 10: 58-60.
- Jahan, S. *et al.*, 2011. Heterotopic pregnancy-case report. J. Bangladesh Coll. Phys. Surg., 29: 44-45.
- Khediri, Z. *et al.*, 2012. Heterotopic pregnancy in spontaneous conception: report of 3 cases and review of literature. Int. J. Case Reports and Imag., 3 (10): 8-11.
- Raziel, A., S. Friedler, A. Herman, D. Strassburger, R. Myymon and R. Ronel, 1997. Recurrent heterotopic pregnancy after repeated *in vitro* fertilization treatment. Hum Rep., 12: 1810-1812.
- Reece, E.A., R.H. Petrie., M.F. Sirmans, M. Finster and W.D. Todd, 1983. Combined intrauterine and extrauterine gestation: a review. Am. J. Obstet. Gynecol., 146: 323-330.