

Effect of Tetracycline on Reproductive Functions in Male Albino Rats

¹K.O. Oyedeji, ²A.F. Bolarinwa and ¹A. Dare

¹Department of Physiology, Faculty of Basic Medical Sciences,
Ladoke Akintola University of Technology, P.M.B. 4000, Ogbomoso, Nigeria

²Department of Physiology, College of Medicine, University of Ibadan, Ibadan, Nigeria

Abstract: Tetracycline is a broad spectrum antibiotic produced by *Streptomyces* genus actinobacteria, indicated for use against many bacterial infections. Several studies have reported its effect on protein synthesis and teratogenicity but there is scanty information on its effect on male reproduction. This study was design to investigate the effect of this drug on serum testosterone level and sperm characteristic in male albino rats. Tetracycline (25 mg kg⁻¹ bw) was administered for 30 days for andrological studies. Distilled water (0.5 mL) serves as the control. Serum testosterone level was assayed using Enzyme Link Immunosorbent Assay (ELISA) and semen analysis was done microscopically, histological analysis of the testis, kidney and liver were also carried out. Data were analysed using the student's t-test at p<0.05. Treatment of rats for 30 days with 25 mg kg⁻¹ bw of tetracycline caused significant decrease in testosterone (0.16 ± 0.04 ng mL⁻¹; relative to the control 1.38 ± 0.53 ng mL⁻¹). Treatment of rats with tetracycline caused significant decrease in sperm motility and sperm count relative to the control; while, there were no significant change in the values of sperm viability and percentage abnormal morphology relative to the control. There was interstitial oedema in the tests. The results from this study suggest that tetracycline has deleterious effect on male reproductive parameter of albino rats.

Key words: Tetracycline, albino rats, testosterone, sperm count, Nigeria

INTRODUCTION

Tetracyclines are broad-spectrum bacteriostatic antibiotics that inhibit protein synthesis. They are active against many gram-positive and gram-negative bacteria including anaerobes, rickettsiae, chlamydiae, mycoplasmas and against some protozoa (Katzung *et al.*, 2009). They are a group of closely related compounds that, as the name implies, consist of four fused rings with a system of conjugated double bonds (Harvey *et al.*, 1997).

Tetracycline has been reported to have antimicrobial effect with iron-chelating property (Grenier *et al.*, 2000). Tetracycline has also been reported to probably has a role in reducing the duration and severity of cholera (Bhattacharya, 2003) and its effects on overall mortality is questioned (Parsi, 2001). Tetracycline has been reported to inhibit the replication of DNA on the cell membrane at high doses (Craig and Stitzel, 1982). Tetracycline has also been reported to be among the antibiotics with high teratogenic risk to humans (Friedman *et al.*, 1990).

However, due to paucity of information from literature on the effect of tetracycline on reproductive parameters in male albino rats; these studies, therefore, aim at investigating the effect of tetracycline on these reproductive parameters.

MATERIALS AND METHODS

Experimental animals: Adult male albino rats weighing between 160 and 180 g bred in the Animal House of Physiology Department, LAUTECH, Ogbomoso were used. They were housed under standard laboratory conditions with a 12 h daylight cycle and had free access to feed and water; they were acclimatized to laboratory conditions for 2 weeks before the commencement of the experiments. All experiments were carried out in compliance with the recommendations of Helsinki's declaration on guiding principles on care and use of animals.

Drug: Tetracycline hydrochloride capsules (Greenfield Pharm., Ltd.) were bought from Jeopat Pharmacy, Ogbomoso, Nigeria.

About 250 mg of tetracycline was dissolved in 10 mL of distilled water to give a concentration of 25 mg mL⁻¹.

Experimental design: Fourteen animals were randomly divided into 2 groups with each group consisting of 7 rats. The 2 groups of rats were subjected to the following oral treatments once a day for 30 days: Group 1

rats received 25 mg kg⁻¹ bw of tetracycline; group 2 rats received 0.5 mL of distilled water as the control group. About 24 h (day 31) after the last dosing of the 2 groups, blood samples were collected and the animals were then euthanized by cervical dislocation for semen analysis. Histological preparation of the tests was also carried out.

Body weight: Body weight of each rat was monitored on weekly basis.

Collection of blood sample: Blood samples were collected through the medial cantus into EDTA bottles for hormonal assay.

Hormonal assay: Plasma samples were assayed for testosterone using the Enzyme-Linked Immunosorbent Assay (ELISA) technique using the Fortress kit.

Semen collection: The testes were removed along with the epididymides. The caudal epididymides were separated from the testes, blotted with filter papers and lacerated to collect the semen.

Semen analysis

Progressive sperm motility: This was done immediately after the semen collection. Semen was squeezed from the caudal epididymis onto a pre-warmed microscope slide (27°C) and two drops of warm 2.9% sodium citrate was added, the slide was then covered with a warm cover slip and examined under the microscope using x400 magnification. Ten fields of the microscope were randomly selected and the sperm motility of 10 sperms was assessed on each field. Therefore, the motility of 100 sperms was assessed randomly. Sperms were labelled as motile, sluggish or immotile. The percentage of motile sperms was defined as the number of motile sperms divided by the total number of counted sperms (i.e., 100) (Mohammad-Reza *et al.*, 2005).

Sperm viability (life/dead ratio): This was done by adding two drops of warm Eosin/Nigrosin stain to the semen on a pre-warmed slide, a uniform smear was then made and dried with air; the stained slide was immediately examined under the microscope using x400 magnification. The live sperm cells were unstained while the dead sperm cells absorbed the stain. The stained and unstained sperm were counted and the percentage was calculated (Laing, 1979).

Sperm morphology: This was done by adding two drops of warm Walls and Ewas stain (Eosin/nigrosin stain can also be used) to the semen on a pre-warmed slide, a uniform smear was then made and air-dried; the stained

slide was immediately examined under the microscope using x400 magnification (Laing, 1979). Five fields of the microscope were randomly selected and the types and number of abnormal spermatozoa were evaluated from the total number of spermatozoa in the five fields; the number of abnormal spermatozoa were expressed as a percentage of the total number of spermatozoa.

Sperm count: This was done by removing the caudal epididymis from the right testes and blotted with filter paper. The caudal epididymis was immersed in 5 mL formol-saline in a graduated test-tube and the volume of fluid displaced was taken as the volume of the epididymis. The caudal epididymis and the 5 mL formol-saline were then poured into a mortar and homogenized into a suspension from which the sperm count was carried out using the improved Neubauer haemocytometer under the microscope.

Testicular histology: After weighing the testes, they were immediately fixed in Bouin's fluid for 12 h and the Bouin's fixative was washed from the samples with 70% alcohol. The tissues were then cut in slabs of about 0.5 cm transversely and the tissues were dehydrated by passing through different grades of alcohol: 70% alcohol for 2 h, 95% alcohol for 2 h, 100% alcohol for 2 h, 100% alcohol for 2 h and finally 100% alcohol for 2 h. The tissues were then cleared to remove the alcohol, the clearing was done for 6 h using xylene. The tissues were then infiltrated in molten paraffin wax for 2 h in an oven at 57°C, thereafter the tissues were embedded. Serial sections were cut using rotary microtome at 5 µm. The satisfactory ribbons were picked up from a water bath (50-55°C) with microscope slides that had been coated on one side with egg albumin as an adhesive and the slides were dried in an oven. Each section was deparaffinized in xylene for 1 min before immersed in absolute alcohol for 1 min and later in descending grades of alcohol for about 30 sec each to hydrate it. The slides were then rinsed in water and immersed in alcoholic solution of hematoxylin for about 18 min. The slides were rinsed in water, then differentiated in 1% acid alcohol and then put inside a running tapwater to blue and then counterstained in alcoholic eosin for 30 sec and rinsed in water for a few seconds, before being immersed in 70%, 90% and twice in absolute alcohol for 30 sec each to dehydrate the preparations. The preparations were cleared of alcohol by dipping them in xylene for 1 min. Each slide was then cleaned, blotted and mounted with DPX and cover slip and examined under the microscope. Photomicrographs were taken at x40, x100 and x400 magnifications.

Statistical analysis: The mean and Standard Error of Mean (SEM) were calculated for all values. Comparisons between the control and the treated groups were done using the student's t-test. Differences were considered statistically significant at $p < 0.05$.

RESULTS AND DISCUSSION

Effect on body weight: Treatment of rats for 30 days with 25 mg kg^{-1} bw of tetracycline caused non-significant ($p > 0.05$) decrease in testosterone levels relative to the control (Fig. 1).

Effect on hormonal levels: Treatment of rats for 30 days with tetracycline (25 mg kg^{-1} bw) caused significant ($p < 0.05$) decrease in testosterone levels relative to the control (Fig. 2).

Effect on sperm characteristics: Treatment of rats for 30 days with tetracycline (25 mg kg^{-1} bw) caused significant ($p < 0.05$) decrease in sperm motility relative to the control. Tetracycline (25 mg kg^{-1} bw) caused non-significant ($p > 0.05$) decrease in sperm viability (life/dead) as well as non-significant ($p > 0.05$) increase in the percentage of abnormal sperm cells. Tetracycline (25 mg kg^{-1} bw), however caused significant ($p < 0.05$) decrease in sperm count (Fig. 3 and 4).

Histopathological observations: Treatment of rats for 30 days with tetracycline (25 mg kg^{-1} bw) caused mild interstitial oedema but normal germinal epithelium; however, the control presented with normal intersitium (Fig. 5 and 6).

Tetracycline caused non-significant changes in body weight of rats after treatment for 30 days, this suggests that tetracycline was not toxic to the animals as well as non-androgenic in activity, since androgens are known to possess anabolic activities. Similar report was given by Gonzales *et al.* (2006) in rats treated with *Lepidium meyenii* extracts.

Tetracycline caused significant decrease in testosterone levels. Similar report was given by Das *et al.* (2009) in rats treated with *Aegle mermelos* extract. This decrease in testosterone levels could indicate that aspirin inhibit the mechanism intervening in the process of hormone synthesis in the Leydig cells.

The andrological results show that treatment of rats for 30 days with tetracycline caused significant decrease in sperm motility. Similar report was given by Venma *et al.* (2002) in rats treated with *Sarcostemma acidum* extract. This suggests that tetracycline was able to permeate the

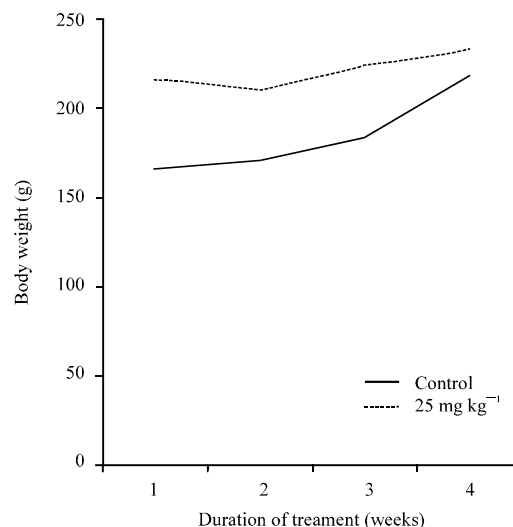


Fig. 1: Body weight changes in control rats and rats treated with tetracycline (25 mg kg^{-1} bw) for 30 days

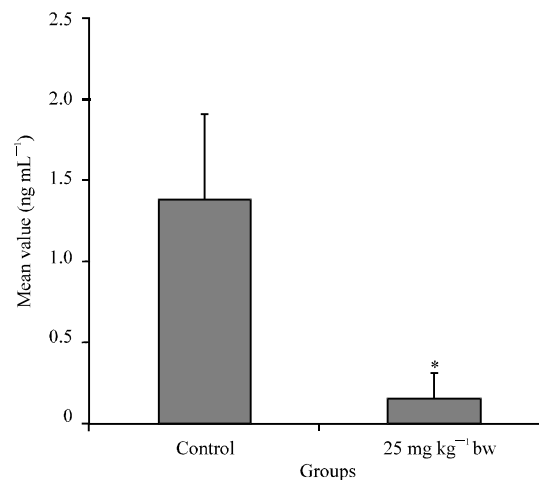


Fig. 2: Effect of treatment of rats for 30 days with tetracycline (25 mg kg^{-1} bw) on plasma testosterone level (ng mL^{-1}) ($n = 7$, $*p < 0.05$)

blood-testis barrier with a resultant alteration in the microenvironment of the seminiferous tubules, since it has been reported that the decrease in sperm motility caused by chemical agents was due to their ability to permeate the blood-testis barrier (Baldessarini, 1980) and thus, creating a different microenvironment in the inner part of the wall of the seminiferous tubules from that in the outer part (Bloom and Fawcett, 1975).

Tetracycline caused non-significant decrease in sperm viability as well as non-significant increase in the percentage of morphologically abnormal sperm cells in the treated rats. This could be due to the ability of

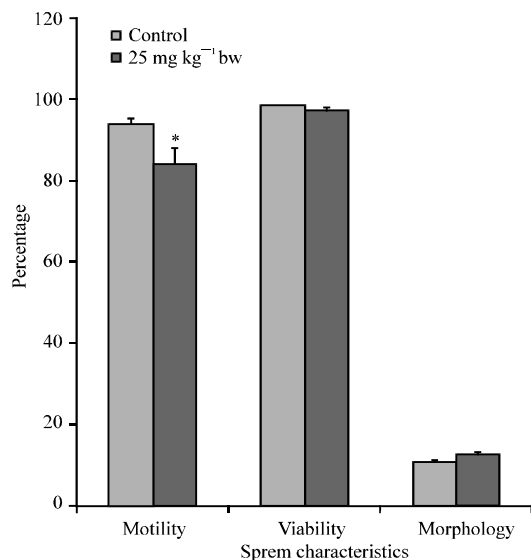


Fig. 3: Spermogram showing the effect of 25 mg kg⁻¹ bw of tetracycline on sperm characteristics after treatment of rats for 30 days (n = 7, *p<0.05)

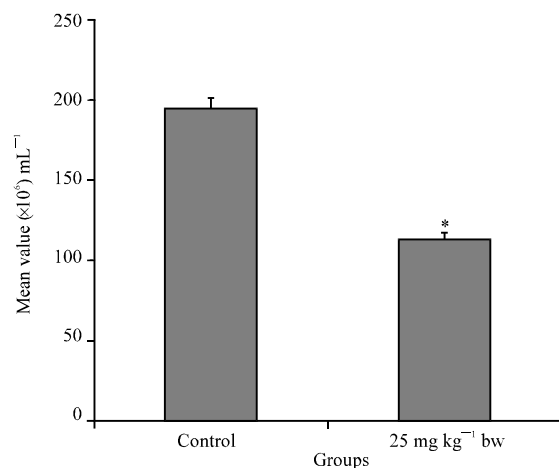


Fig. 4: Spermogram showing the effect of 25 mg kg⁻¹ bw of tetracycline on sperm count after treatment of rats for 30 days (n = 7, *p<0.05)

tetracycline to either interfere with the spermatogenic processes in the seminiferous tubules, epididymal functions or activities of testosterone on hypothalamic release factor and anterior pituitary secretion of gonadotropins which may result in alteration of spermatogenesis (William, 2000; Bowman and Rand, 1985).

Tetracycline caused significant decrease in sperm count of the treated rats which could be as a result of decrease in plasma levels of testosterone, since this hormone has been reported to be important in the

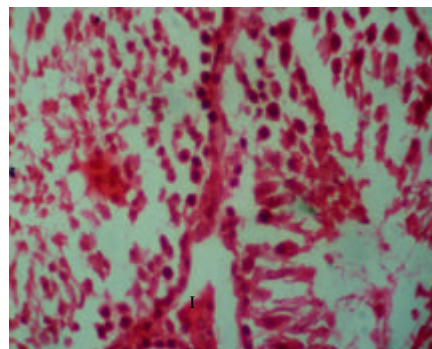


Fig. 5: Effect of 0.5 mL distilled water (control) on the testis after treatment of rat for 30 days (x400); photomicrograph showing normal Interstitium (I) with normal Germinal Epithelium (GE)

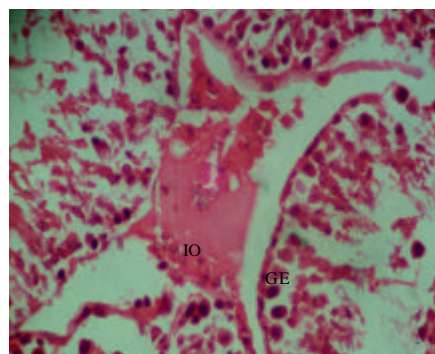


Fig. 6: Effect of 25 mg kg⁻¹ bw of tetracycline on the testis after treatment of rat for 30 days (x400); photomicrograph showing Interstitial Oedema (IO) with normal Germinal Epithelium (GE)

initiation and maintenance of spermatogenesis (Christensen, 1975). Similar report was given by Krishnamoorthy *et al.* (2007) in *Terminalia chebula* extract treated rats.

CONCLUSION

Treatment of rats with tetracycline caused mild interstitial oedema. Similar result was reported by Manna *et al.* (2005) in rats treated with deltamethrin. This could be due to:

- Increased hydrostatic pressure
- Reduced oncotic pressure
- Lymphatic obstruction
- Sodium retention (Kumar *et al.*, 1999)

REFERENCES

- Baldessarini, R.J., 1980. Drugs and the Treatment of Psychiatric Disorders. In: The Pharmacological Basis of Therapeutics, Goodman, L.S. and A. Gilman (Eds.). Macmillan Publishing Co., New York, pp: 301-417.
- Bhattacharya, S.K., 2003. An Evaluation of current cholera treatment. Expert Opin. Pharmacother., 4: 141-146.
- Bloom, W. and D.W. Fawcett, 1975. Male Reproductive System. In: The Textbook of Histology, Bloom, W. and D.W. Fawcett (Eds.). Saunders Co., Philadelphia.
- Bowman, W.C. and M.J. Rand, 1985. The Reproductive System and Drugs Affecting the Reproductive Systems. In: Textbook of Pharmacology, Bowman, W.C. and M.J. Rand (Eds.). 2nd Edn, Blackwell Scientific Publications, Oxford, pp: 1-8.
- Christensen, A.C., 1975. Leydig Cell. In: Handbook of Physiology, Greep, P.O. and E.B. Astwoods (Eds.). American Physiological Society, Washington, DC.
- Craig, C.R. and R. Stitzel, 1982. Modern Pharmacology. 1st Edn., Little, Brown and Co., New York, pp: 653-655.
- Das, U.K., D. De, K. Chatterjee, C. Mallick, T.K. Bera and D. Ghosh, 2009. Antigonadal effect induced by hydro-methanolic extract of leaf of *Aelgle mermelos* in male rat: Effect of hCG co-administration. J. Med. Plants Res., 3: 728-735.
- Friedman, J.M., B.B. Little, R.L. Brent, J.F. Cordero, J.W. Hanson and T.H. Shepard, 1990. Potential human teratogenicity of frequently prescribed drugs. Obstetrics Gynecol., 75: 594-599.
- Gonzales, C., J. Rubio, M. Gasco, J. Nieto, Y. Sandra and G.F. Gonzales, 2006. Effect of short-term and long-term treatments with three ecotypes of *Lepidium meyenii* (MACA) on spermatogenesis in rats. J. Ethnopharmacol., 103: 448-454.
- Grenier, D., M. Hout and D. Mayrand, 2000. Iron-chelating activity of tetracyclines and its impact on the susceptibility of *Actinobacillus actinomycetemcomitans* to these antibiotics. Antimicrob. Agents Chemother., 106: 763-766.
- Harvey, R.A., P.C. Champe, M.J. Mycek and B.D. Fisher, 1997. Lippincott Illustrated Reviews: Pharmacology. 2nd Edn., Lippincott-Raven, Philadelphia, pp: 311-314.
- Katzung, B.G., S.B. Masters and A.J. Trevor, 2009. Basic and Clinical Pharmacology. 11th Edn., McGraw-Hill, New York, USA., ISBN-13: 9780071604055, pp: 796-799.
- Krishnamoorthy, P., S. Vaithinathan, A. Vimal-Rani and A. Bhuvaneshwari, 2007. Effect of *Terminalia chebula* fruit extract on lipid peroxidation and antioxidative system of testis of albino rats. Afr. J. Biotechnol., 6: 1888-1891.
- Kumar, V., A.K. Abbas and N. Fausto, 1999. Pathology Bases of Disease. 7th Edn., Elsevier Saunders, China, Pages: 122.
- Laing, J.A., 1979. Fertility and Infertility in Domestic Animals. 3rd Edn., Bailliere Tindall, London.
- Manna, S., D. Bhattacharyya, T.K. Mandal and S. Das, 2005. Repeated dose toxicity of deltamethrin in rats. Indian J. Pharmacol., 37: 160-164.
- Mohammad-Reza, P., D. Farzaneh, T.K. Taherch and P.P. Zoherb, 2005. The effects of hydroalcoholic extract of *Actinidia chinensis* on sperm count and motility and blood levels of estradiol and testosterone in male rats. Ach. Iranina Med., 8: 211-216.
- Parsi, V.K., 2001. Cholera. Prim. Care Update Ob. Gyns, 8: 106-109.
- Venma, P.K., A. Sharma, A. Mathur, P. Sharma, R.S. Gupta, S.C. Joshi and V.P. Dixit, 2002. Effect of *Sarcostemma acidum* stem extract on spermatogenesis in male albino rats. Asian J. Androl., 4: 43-47.
- William, K.W., 2000. Hormones and Hormone Antagonists. In: Remington: The Science and Practise of Pharmacy, Gennaro, A.R. (Ed.). Vol. 11, 20th Edn., Lippincott Williams and Wilkins, Baltimore, Md., pp: 1390-1391.