

Clinical and Radiographic Success of Low Level Laser Therapy (LLLT) on Primary Molars Pulpotomy

Mojtaba Vahid Golpayegani, Ghassem Ansari and Nikoo Tadayon
Department of Pediatric Dentistry, Dental School, Shahid Beheshti University MC., Tehran, Iran

Abstract: Low Level Laser Therapy (LLLT) is increasingly in use over the last few decades in both medicine and dentistry. It has been suggested that LLLT may be helpful in pulpal wound healing following its exposure. The purpose of this study was to compare the effectiveness of LLL energy using a diode laser to enhance healing of remaining pulp in comparison to Formocresol (FC) effect following pulp amputation in primary molars. A total of 23 contralateral pairs of teeth from 11 children aged 4-7 years were selected and matched using clinical and radiographic conditions. One tooth from each pair was randomly assigned to the LLLT pulpotomy while the other one for FC pulpotomy group. Each tooth was checked in 6 months for its clinical and radiographical reactions. About 8 patients returned in this review appointment while other 3 still waiting for full 6 months term. These results are from 18 teeth in each group. Almost all teeth controlled from the case and control groups were representing no complications. This was while radiographic assessment resembled two teeth with signs of periradicular radiolucency in LLLT group. Findings of this investigation show that LLLT can be used successfully as a complementary step to pulpotomy procedure in view to help the healing of amputated pulp. Longer follow-up periods are recommended on LLLT pulpotomy to support long term effect of the technique on pulp.

Key words: Laser, pulpotomy, LLLT, primary teeth, clinical, Iran

INTRODUCTION

Pulpotomy is one of the most frequently used treatments for retaining cariously involved primary molars that would otherwise be extracted (American Academy of Pediatric Dentistry, 2002). Formocresol (FC) has long been considered as a widely approved pulpotomy medicament for treating teeth for decades. It is considered the most universally thought and preferred pulp therapy for primary teeth among dentists (Primosch *et al.*, 1997; Vij *et al.*, 2004).

However, the use of FC as a pulpotomy agent has recently been challenged due to its systemic distribution, pulpal inflammatory response, cytotoxicity and carcinogenic potentials (Ranly and Fulton, 1976; Rolling *et al.*, 1976; Myers *et al.*, 1978).

Furthermore, the International Agency for Research on Cancer (IARC) classified formaldehyde as carcinogenic to humans in June 2004 leaving the profession to look for other viable alternatives to FC. These include: glutaraldehyde, ferric sulfate, MTA, calcium hydroxide, electrosurgery, laser and biologic materials (Srinivasan *et al.*, 2006). One promising alternative to formocresol pulpotomy is also Low Level

Laser Therapy (LLLT) which has been shown to accelerate wound healing process in exposed dental pulp tissue (Utsunomiya, 1998). Therapeutic laser treatment, also referred to as LLLT has been used for the last 3 decades.

The lack of recognition among clinicians and researchers is due in part to the weakness of published materials. However, a growing number of clinicians are using LLLT in their daily practice because of visible success gained (Sun and Tuner, 2004). When low-level laser light provides the energy that interacts with the cells, it is believed to create a myriad of positive functions such as accelerated wound healing, pain relief, regeneration and immune enhancement (Sun and Tuner, 2004). It is noninvasive, nonpharmaceutical and more over economical (Sun and Tuner, 2004).

No side effects of such LLLT application has been reported yet (Sun and Tuner, 2004). Low-power lasers have been successfully used and it is known that wound healing is accelerated by their irradiation in dental practice (Ohbayashi *et al.*, 1999). The purpose of this investigation was to compare the effectiveness of LLLT as a complementary step to pulpotomy process in primary molars to that of conventional Formocresol.

MATERIALS AND METHODS

A group of healthy children attending of Pedodontics Department, Faculty of Dentistry, Shahid Beheshti Medical University (SBMU), Tehran were invited to participate in this study. An Ethic approval was obtained from Ethics Review Committee of SBMU to conduct this clinical study. Children with at least 2 contralateral primary carious molars having similar size cavities were included for this investigation. Patients aged 4-7 years were only included in order to allow a more precise pulpal reaction following LLLT/FC application. Full detailed treatment plans were explained to the parents and informed consents were obtained prior to the investigation. About 46 teeth were selected for this preliminary study. The criteria for tooth selection were as follows (Fuks *et al.*, 1998; Liu *et al.*, 1999; Eidelman *et al.*, 2001; Agamy *et al.*, 2004; Saltzman *et al.*, 2005):

- Having a vital pulp with carious exposures
- No clinical signs or symptoms of pulp degeneration such as swelling, fistula, pathologic mobility, excessive bleeding from amputated radicular stumps, spontaneous or nocturnal pain and tenderness to percussion or palpation was noted
- Absence of any radiographic signs of internal and pathologic external resorption and periapical or interradericular radiolucency
- Less than 1/3 of root had been physiologically resorbed
- Restorable with SSCs

Preoperative periapical radiographs were obtained from each tooth prior to treatment. The contralateral teeth were randomly assigned to either the LLLT or FC group, in order to allow proper randomization eliminating possible bias. Each tooth was isolated following administration of a local anesthesia. Caries removal was performed followed by coronal access opening to the pulp chamber using a no. 330 high-speed bur with water spray. The coronal pulp was then amputated using a sharp spoon excavator or a slowly revolving round carbide bur. Pulp chamber was then irrigated with a light flow of distilled water. Cotton pellet moistened with saline was placed on the pulp stumps in order to achieve hemostasis. A cotton pellet with diluted FC (1:5 Buckley's solution) was placed in contact with the pulp in FC group and left for 5 min. This was while the pulp was irradiated using a semiconductor diode laser device (BTL 5000, Prague, Czech Republic) with wavelength of 632 nm in the experimental group (Fig. 1). The laser application was in continuous mode with the total energy of one spot, corresponding to 2 min and 31 sec exposure was



Fig. 1: BTL 5000; laser device used in this investigation

4 J cm⁻². The laser beam was delivered through a 0.5 mm diameter optical fiber with the distance from the tip of the fiber to the pulp stump being 2 mm. All patients and clinical staff were requested to wear appropriate eye protection goggles during laser application.

Plain ZOE (The L.D. Caulk Division, Dentsply International Inc. Milford, Del) was placed over the pulp stumps as the base and a second layer of reinforced ZOE (The L.D. Caulk Division, Dentsply International Inc. Milford, Del) was then condensed on top for filling the pulp chamber space. Each tooth was then restored with SSC as planned. All the treated teeth in both groups were reviewed in 6 and 12 months using clinical and radiographic criteria (Fuks *et al.*, 1998; Liu *et al.*, 1999; Eidelman *et al.*, 2001; Agamy *et al.*, 2004; Saltzman *et al.*, 2005).

Clinical criteria: No pain; no abnormal tooth mobility; no swelling; no sinus tract and no sensitivity to percussion or pressure.

Radiographic criteria: No periapical radiolucency; no inter-radicular radiolucency; no pathologic external resorption; no pathologic internal resorption and no widening of PDL. Clinical and radiographic outcome assessment was made by two independent experienced clinicians (pedodontists) who were blind to the treatment. Tooth type and location were analyzed.

RESULTS AND DISCUSSION

Eight children, with a total of 36 pulpotomized primary molars were available for the 6 months follow-up evaluation. Remaining 3 children with 10 pulpotomized molars, failed did not complete their 6 months follow up period and were not calculated in this part of the study. The mean age of the patients was 5.6 years with a range of 4-7 years. Tooth type was distributed in the following manner: 10 (27.8%) upper first molars, 12 (33.3%) lower first molars, 6 (16.7%) upper

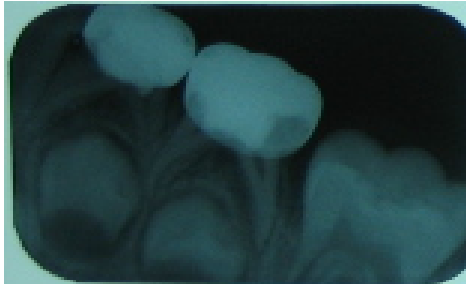


Fig. 2: Radiographic view shows no pathologic sign of failure following pulp treatment using LLLT in 12 months follow up

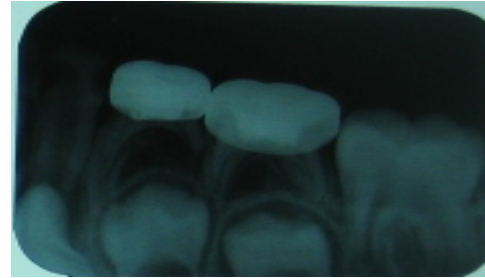


Fig. 4: Pathologic sign of failure following pulp treatment using Formocresol in 12 months follow up, note the forcation lesion

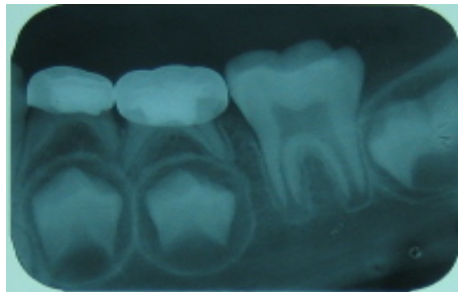


Fig. 3: Radiographic view shows no pathologic sign of failure following pulp treatment using Formocresol in 12 months follow up

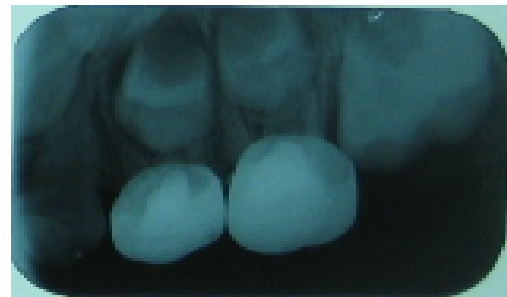

Fig. 5: Pathologic sign of failure following pulp treatment using LLLT in 12 months follow up, note the PDL widening along the root as well as signs of internal resorption

second molars and 8 (22.2%) lower second molars. About 100% (18/18) of LLLT and 100% (18/18) of the FC pulpotomies were clinically found to be sound and without complication. Radiographic assessment showed some radiolucent changes in two cases (11%) of the teeth treated with LLLT at 6 months which were subsequently extracted. The remaining 16 pairs of teeth had a second drop of a pair due to no attendance at 1 year follow up. Of this remaining 15 pair, a single case reported spontaneous pain from FC group with the rest having no sign or symptoms at all. Most of the cases had evidences of both clinical and radiographic success with no complications (Fig. 2 and 3). Radiographic review of cases in 12 month follow up revealed that 3 cases of LLLT group and 5 of the FC had at least one sign of pulp treatment failure (Fig. 4 and 5) (Table 1). No significant differences were found between the radiographic findings of the two groups in 12 months using McNemar's test ($\alpha = 0.05$).

Dilute FC is still regarded as the gold standard for pulpotomy of the primary teeth (Primosch *et al.*, 1997; Vij *et al.*, 2004) but concerns on cytotoxicity and potential mutagenicity are also maintained as obstacles on this

Table 1: Results of clinical and radiographic evaluations in 6 and 12 months

Age	FC/LLLT	Success	Failure	Sum
6 months	Success	15	0	15
	failure	3	0	3
Total		18	0	18
12 months	Success	10	2	12
	failure	0	3	3
Total		12	5	15

issue (Ranly and Fulton, 1976; Rolling *et al.*, 1976; Myers *et al.*, 1978). To date, there are several techniques for pulp treatment in primary teeth with a range of protocols and medicaments suggested for different clinical situations (Nadin *et al.*, 2003). A consensus has not been reached on the ideal pulpotomy technique, however, as the majority of the research has not involved randomized clinical trials (Nadin *et al.*, 2003). The existing paucity of information is in conflict for its success to current pulpotomy technique. Furthermore, the need to find out an alternative to formocresol is still on top of the research list. In this respect, Pescheck *et al.* (2002) looked at the effect of a Diod laser pulpotomy in primary teeth survival and concluded that the device could be considered as a favorable alternative to achieve a more precise and reliable hemostasis at pulp stumps

(Pescheck *et al.*, 2002). The application of LLLT in dentistry includes various clinical conditions. The general rule for intra-oral treatment is to use 2-4 J with the intra-oral probe and 4-10 J for extra-oral treatments (Sun and Tuner, 2004). The results of a meta-analysis study indicate that 632 nm wavelength has the most significant treatment effect on tissue repair, however, the researchers stated that these results should be interpreted with great caution as their effort to pinpoint the wavelength that is most beneficial for tissue healing was severely limited by the number of studies that met their inclusion criteria (Enwemeka *et al.*, 2004). Contact mode is needed for all applications with one exception. Treating an open wound requires a 2-4 mm distance between the laser and the target tissue under the condition called non contact mode (Sun and Tuner, 2004). This investigation was the first to look at the effect of LLLT as a pulpotomy technique in primary molars in a randomized clinical trial. As the results are showing a high clinical and radiographic success rate with LLLT at 6 months was obtained (100 and 89%, respectively). Dilute FC as the control technique in this study has also shown a clinical success rate of 100% with its radiographic findings representing success rate of 100%.

Since first described by Mester, low power lasers, generally, ≤ 500 mW in average power have been found to have useful medical applications in the field of wound healing (Enameka *et al.*, 2004; Ferreira *et al.*, 2006). The process of tissue repair may be subdivided into three major phases: inflammation, cell proliferation and tissue maturation. Previous reports showed that all these three phases are positively affected by low power laser treatment (Enameka *et al.*, 2004).

In addition, the biologic effects of LLLT have been looked at by means of histopathology of the pulp tissue by Utsunomiya (1998). Results of which suggest that LLLT accelerates wound healing of the pulp and the expression of the lectins and collagens. The formation of calcified nodules in human dental pulp fibroblasts are enhanced, as well as in alkaline phosphatase activity, the production of collagen and osteocalcin by laser irradiation (Ohbayashi *et al.*, 1999). The positive effect of LLLT was reported on reactional dentinogenesis induction in human teeth by Ferreira *et al.* (2006). The use of GaAlAs laser with wavelength of 670 nm and energy density of 4 J cm^{-2} caused biomodulation activity on the dental pulp cells, biostimulation of reactional dentinogenesis and promotion of a less intense inflammation process when used *in vivo* on class V cavity preparations. The researchers concluded that its use constitutes a therapeutic modality for vital pulp therapy. Kurumada (1990) used GaAs laser light in vital pulpotomy procedures. Laser irradiation induced enhancement of calcification in the wound surface and stimulated

formation of calcified tissue. Nagasawa *et al.* (1991) has observed that Nd:YAG and argon laser irradiation with low level doses strongly stimulate the formation of secondary dentin. The use of a low level laser on dentine pulp interface of a series of permanent premolars suggests that this energy accelerate the recovery of the dental structure following cavity preparation (Godoy *et al.*, 2007). Overall, the evidence described by these studies, along with the findings in this study, lend support to the use of LLLT as a complement in pulpotomy process of primary molars. A larger sample size and longer-term follow-up could enhance the findings for a better and more appropriate comparison of the two treatment modalities.

CONCLUSION

Calculated data shows that Low Level Laser Therapy (LLL) is equal to Formocresol (FC) as a complement to pulpotomy procedure and in absence of FC in primary molars.

REFERENCES

- Agamy, H.A., N.S. Bakry, M.M.F. Mounir and R. Avery, 2004. Comparison of MTA and formocresol as pulp capping agents in pulpotomized primary teeth. *Pediatr. Dent.*, 6: 302-309.
- American Academy of Pediatric Dentistry, 2002. Reference manual 2002-2003. Guidelines on pulp therapy for primary and young permanent dentition. *Pediatr. Dent.*, 24: 86-90.
- Eidelman, E., G. Holan and A.B. Fuks, 2001. Mineral trioxide aggregate vs. formocresol in pulpotomized primary molars: A preliminary report. *Pediatr. Dent.*, 23: 15-18.
- Enwemeka, C.S., J.C. Parker, D.S. Dowdy, E.E. Harkness, L.E. Sanford and L.D. Woodruff, 2004. The efficacy of low-power lasers in tissue repair and pain control: A meta-analysis study. *J. Photomed. Laser Surg.*, 22: 323-329.
- Ferreira, A.N.S., L. Silveira, W.J. Genovese, V.C. de Araujo, L. Frigo, R.A. de Mesquita and E. Guedes, 2006. Effect of GaAlAs laser reactional dentinogenesis induction in human teeth *J. Photomed. Laser Surg.*, 24: 358-365.
- Fuks, A.B., G. Holan, J.M. Davis and E. Eidelman, 1998. Ferric sulfate versus dilute formocresol in pulpotomized primary molars: Long term follow up. *Pediatr. Dent.*, 19: 327-330.
- Godoy, B.M., C.V.E. Arana, S.E. Nurez and M.S. Ribeiro, 2007. Effect of low-powered laser on dentine-pulp interface after cavity preparation: An ultrastructural study. *Arch. Oral Biol.*, 52: 899-903.

- Kurumada, F., 1990. A study on the application of Ga-As semiconductor laser to endodontics: The effect of laser irradiation on the activation of inflammatory cells and the vital pulpotomy. *Ou. Daigaku. Shigakushu.*, 17: 233-244.
- Liu, J.F., L.R. Chen and S.Y. Chao, 1999. Laser pulpotomy of primary teeth. *Pedia. Dent.*, 21: 128-129.
- Myers, D.R., H.K. Shoaf, T.R. Dirksen, D.H. Pashley, G.M. Whitford and K.E. Reynolds, 1978. Distribution of 14 c-formaldehyde after pulpotomy with formocresol. *J. Am. Dent. Assoc.*, 96: 805-813.
- Nadin, G., B.R. Goel, C.A. Yeung and A.M. Glenney, 2003. Pulp treatment for extensive decay in primary teeth. *Cochrane Database Systematic Rev.* DOI: 10.1002/14651858.CD003220
- Nagasawa, A., A. Negishi and K. Kato, 1991. Clinical applications of LLLT in dental and oral surgery in the Urawa Clinic. *Laser Therapy*, 3: 119-122.
- Ohbayashi, E., K. Matsushima, S. Hosoya, Y. Abiko and M. Yamazaki, 1999. Stimulatory effect of laser irradiation on calcified nodule formation in human dental pulp fibroblasts. *J. Endod.*, 25: 30-33.
- Pescheck, A., B. Pescheck and A. Moritz, 2002. Pulpotomy of primary molars with the use of a carbon dioxide laser: Results of a long term *in vivo* study. *J. Oral Laser Appl.*, 2: 165-169.
- Primosch, R.E., T.A. Glom and R.G. Jerrell, 1997. Primary tooth pulp therapy as thought in predoctoral pediatric dental programs in the United States. *Pediatr. Dent.*, 19: 118-122.
- Ranly, D.M. and R. Fulton, 1976. Reaction of rat molar pulp tissue to Formocresol, formaldehyde and cresol. *J. Endod.*, 2: 176-181.
- Rolling, I., G. Hasselgren and L. Tronstad, 1976. Morphologic and enzyme histochemical observations on pulp of human primary molars 3 to 5 years after Formocresol condition. *Oral Surg.*, 42: 518-518.
- Saltzman, B., M. Sigal, C. Clokie, J. Rukavina, K. Titley and G.V. Kulkarni, 2005. Assessment of a novel alternative to conventional formocresol-zinc oxide eugenol pulpotomy for the treatment of pulpally involved human primary teeth: Diode laser-mineral trioxide aggregate pulpotomy. *Int. J. Pediatr. Dent.*, 15: 437-447.
- Srinivasan, V., C.L. Patchett and P.J. Waterhouse, 2006. Is there life after Buckley's Formocresol? Part I---a narrative review of alternative interventions and materials. *Int. J. Paediatr. Dent.*, 16: 117-127.
- Sun, G. and J. Tuner, 2004. Low level laser therapy in dentistry. *J. Dent. Clin. N. Am.*, 48: 1061-1076.
- Utsunomiya, T., 1998. A histopathological study of the effects of low-power laser irradiation on wound healing of exposed pulp tissues in dogs, with special reference to lectins and collagens. *J. Endod.*, 24: 187-193.
- Vij, R., J.A. Coll, P. Shelton, N.S. Earooq, 2004. Caries control and other variables associated with success of primary molar vital pulp therapy. *Pediatr. Dent.*, 26: 214-220.