

Comparing the Effectiveness of Two Gingival Retraction Procedures on Gingival Recession and Tissue Displacement: Clinical Study

¹Mahmoud Kazemi, ¹Maryam Memarian and ³Venus Loran

¹Department of Prosthodontics, Faculty of Dentistry,
Tehran University of Medical Sciences, Tehran, Iran

²Department of Prosthodontics, Faculty of Dentistry, Kerman University in Kerman, Iran

Abstract: Different techniques have been used for achieving effective gingival retraction without damaging periodontal tissues, while they accompany with some disadvantages in practice. New techniques are required for achieving better management of gingival tissue in addition to be fast and simple. Comparing the effects of Expasyl paste and presaturated gingival cord with aluminum chloride on gingival retraction, recession and inflammation. Ten patients who needed gingival retraction prior to make impression were included in the study. At random, presaturated cord (with $AlCl_3$) or expasyl paste were placed into each buccal-side gingival sulcus of paired posterior teeth. After removing the cord/paste, casts were made. All the casts were bucco-lingually sectioned at the buccal ridge by a rotary diamond disk and the widths of gingival sulcus were measured by a traveling microscope (Edmund optics Inc., barrington, NJ, USA) as the distance from the tooth to the gingival crest. The gingival recession was defined as the distance between the reference line marked on the buccal side of the casted teeth and the gingival level, measured by a jig in 4 phases, 0, 7, 14 and 28 days. The gingival index was evaluated in the 4 phases, too. Data were analyzed using paired t-test or Wilcoxon rank test ($\alpha = 0.05$). The mean width of the retracted sulcus in the presaturated cord group (0.46 ± 0.34 mm) was greater than Expasyl paste group (0.34 ± 0.36 mm, $p < 0.001$). In all the 4 phases, the mean gingival recession in the cord group was significantly greater than Expasyl paste group ($p < 0.001$). The inflammation score was significantly higher in the cord group in compare to the paste group, in 7th day ($p = 0.03$) and 14th day ($p = 0.04$). Based on the findings, gingival retraction with Expasyl paste method caused less injury to gingival tissues than impregnated cord, while both provide gingival retraction.

Key words: Gingival retraction, prosthodontics, effectiveness, tissue displacement

INTRODUCTION

Effective gingival retraction prior to taking an impression without damaging periodontal tissues is very important in long-term success of cast restorations. Poor marginal fit, which is the major cause of failure in cast restorations usually results from incomplete marginal detail in the impression (Donovan *et al.*, 1985; Nemetz and Seibly, 1990; Ferrary *et al.*, 1996; Hansen *et al.*, 1999). Different techniques have been invented and used for this purpose, which mostly had disadvantages such as being painful, the need of an anesthesia, injuring the junctional epithelia and gingival recessions (Hansen *et al.*, 1999; De Gennaro *et al.*, 1982). These disadvantages motivate the use of a new technique, which can overcome them in addition to be fast and simple.

Techniques for gingival retraction have been classified as mechanical, chemical, surgical or a combination of all. The method of gingival displacement

used by the majority of practitioners is a combination of mechanical-chemical retraction, using gingival retraction cords along with specific hemostatic medicaments (Donovan and Chee, 2004). Plain or chemically impregnated cord has been widely used to achieve displacement of the gingival tissues and to control hemorrhage or gingival fluid seepage. Use of these materials has the disadvantages of taking considerable time to soak the cord in the homeostatic solution, to insert and necessarily have to wait for hemostasis and tissue displacement (Donovan and Chee, 2004; Csempeš *et al.*, 2003).

Bowles *et al.* (1991) found that sympathomimetic amines might provide safer and more effective alternatives to retract the sulcus than those agents currently were used.

Ruel *et al.* (1980) and De Gennaro *et al.* (1982) reported an average gingival recession of 0.2 mm after gingival retraction with epinephrine impregnated cord.

Previous histological studies (Hansen *et al.*, 1999; De Gennaro *et al.*, 1982; Akca *et al.*, 2006; Azzi *et al.*, 1983; Kopac *et al.*, 2002; Shaw *et al.*, 1980) demonstrated that placement of the presaturated cord with different retraction medicaments caused a various degree of gingival inflammation, which returned to its normal histologic appearance in 3-24 days.

Feng *et al.* (2006) reported that gingival retraction with plain cord, develop an acute injury that healed clinically in 2 weeks as was indicated by the gingival index. They found no significant change in the attachment loss intraorally at the end of the 4 weeks experimental period.

The gingival crevice normally is approximately only 2 mm in depth and must treated with caution, thus, whatever means is used to expose the tooth margins and control bleeding and moisture, it must be 1 that is conservative so as not to cause detachment of the tissue from the tooth or cause injury to the tissue, either mechanical or chemical, that might result in permanent tissue recession.

According to Laufer *et al.* (1994, 1996) a 0.2-0.4 mm horizontal displacement of free gingival margin provides sufficient space for an adequate bulk of impression material at the apical aspect under the chamfer or shoulder thereby, preventing distortion or disruption on removal of the impression. So, the critical sulcular width is probably 0.2 mm. with sulcular width smaller than this the impression material behaves in an unpredictable manner.

Also they found Rateitschak (1989) and Fazekas *et al.* (2002) with a displacement time 8 min, the line angle crevice closed to <0.2 mm within 60 sec after cord removal. This is the area of concern when impression of multiple abutment is made, as the crevice of the last abutment may close considerably before the wash impression material has flowed in to it. So, in these clinical situations, a simple and fast technique is recommended.

A new retraction material (Expasyl; Pierre Rolland, Noisy le Sec, France) was recently proposed for dentistry to displace gingival tissue without damaging it before impression making. Usage of this material is much easier and faster than the presaturated retraction cord. It is a paste which is composed of Aluminum chloride 15%, kaolin and excipients for temporary gingival retraction. It is introduced slowly in to the sulcus (2 mm sec⁻¹) and then removed by an air and water spray.

This new material has not been examined as a potential gingival retraction method. The aim of this study was to compare the effects of 2 different mechanicochemical retraction methods, the expasyl paste and presaturated gingival cord with Aluminum Chloride (AlCl₃) solution in gingival retraction, recession and

inflammation. The research hypothesis was that gingival retraction with Expasyl paste would have made fewer traumas to the gingival tissues but it might not be effective enough in retraction of free gingival margin.

MATERIALS AND METHODS

The protocol of this study was revised and approved by the institutional research board of Dental Research Center, Tehran University of Medical Sciences, Tehran, Iran. Informed consent was obtained from all participants.

Twenty specimens of posterior teeth from patients with ages between 21 and 48, who had no significant medical problems were selected by simple randomization method. Healthy periodontium and required fixed partial denture in both sides of the same arch were the main characteristics of the patients. All patients had no history of smoking, alcohol abuse, or using specific drugs. Each patient was selected with the following periodontal status: plaque index 0, gingival sulcus depth between 1-2 mm, normal contour of gingiva and no bleeding on probing. First, tooth preparation with slope shoulder finishing line was performed from the mesiobuccal line angle to distobuccal line angle at the height of the free gingival margin to avoid to avoid tissue damage (Tebrock, 1986). Then, each tooth was marked in the middle third of the buccal surface with NO 38 inverted con bur as a reference line (Fig. 1).

A combination of light and heavy bodied silicone impression (Speedex; ColteneAG, Altstätten, Switzerland) -incorrect-see Guidelines and cite manufacturing info correctly throughout) was made by using a custom acrylic tray and the cast was poured with improved laboratory stone (Type IV; FujiRock; GC, Tokyo, Japan, city missing, Japan). The teeth from molar or premolar regions were isolated and the retraction medium was placed in to the buccal gingival sulcus: Plain cord (ultrapak knitted retraction cord #1; Ultradent Inc, South Jordan, Utah) presaturated with 15% aluminum chloride solution (Stat; Germiphen, Brantford, Canada) in one side was remained for 10 min and Expasyl paste in the other side of the same arch, which was remained in the site for 2 min (Fig. 2 and 3).

The cord was removed while moist and Expasyl were washed out by an air and water spray, followed by a second impression and its cast was made. Sections of the casts were sawed out, the teeth were sectioned baccollingly at the buccal ridge with a rotary diamond disk followed by quantitative measurement of the width (in mm) of the retracted sulcus, under a traveling microscope (Edmund optics Inc, Barrington, NJ, USA), as the distance from the tooth to the crest of the gingival

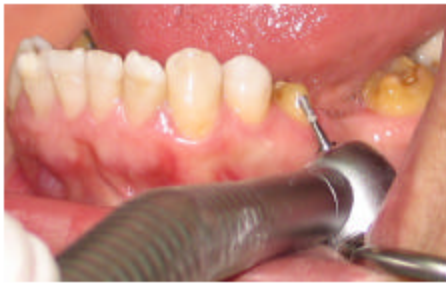

Fig. 1: Marked teeth in middle third of buccal surface

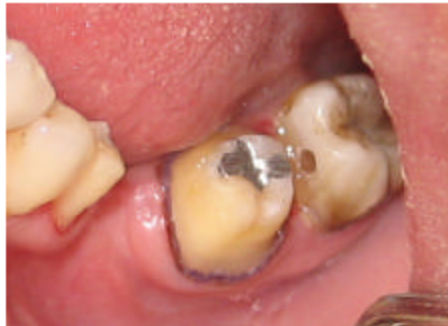

Fig. 2: Use of saturated gingival cord with aluminum chloride

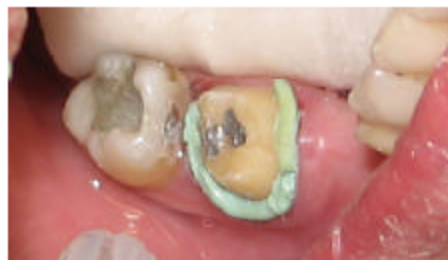

Fig. 3: Use of expasyl paste for gingival retraction

(Fig. 4). For the fabrication of provisional restorations a poly (methylmetacrylate) acrylic resin (Duraly, Reliance, Worth, Illinois, USA) city, state?) was used. The provisionals were indirectly made on a yellow stone casts made from an irreversible hydrocolloid impression. The acrylic resin restorations were adjusted and then polished with pumice slurry and high-shine acryluster material on a 4" rag wheel. The provisional restorations were cemented with zinc oxide eugenol temporary cement (Temp-Bond; Kerr, S.P.A, Italia).

Seven, fourteen and twenty eight days following gingival retraction, other impressions were made and the gingival recession was measured as the distance from original mark to the crest of the gingiva, which have

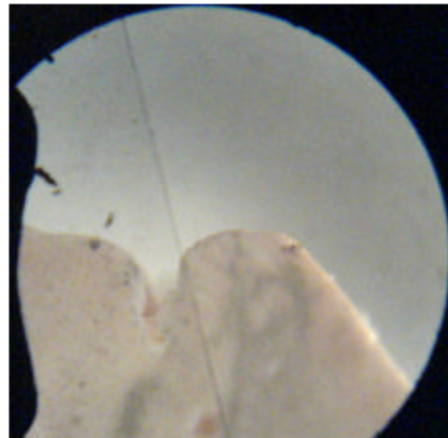


Fig. 4: Width of the retracted sulcus was measured under a traveling microscope as the distance from the tooth to the gingival crest

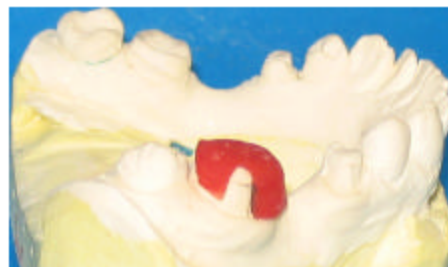

Fig. 5: Distance from original mark to the crest of the gingiva determined with a jig

determined with an acrylic resin (Pattern resin; GC, America Inc, Alsip, IL) jig (Fig 5). The Jig was well-adapted with the prepared teeth on all 4 casts. Both Plaque index (Laufer *et al.*, 1997) (Silness and Loe) and gingival inflammation, were assessed at the same visit session.

All data were analyzed by using the statistical program of social science (SPSS Inc, Chicago, USA). Two statistical methods were used to evaluate the results: paired-t-test was used to compare the statistical significance of gingival recession and amount of gingival retraction between groups (retraction cord and Expasyl paste) and the Wilcoxon signed ranks test was used to show the statistical significance of gingival inflammation between 2 groups. The level of significance was $p < 0.05$.

RESULTS AND DISCUSSION

The average width of the gingival sulcus of each group is shown in Table 1 the mean width of the retracted

Table 1: Statistical evaluation of mean sulcular width (mm) in both groups

Sulcular width	Mean	SD	SEM
CO	0.46	0.03	0.007
EX	0.34	0.04	0.008

CO: Cord; EX: Expasyl; (p<0.001) statistically significant

sulcus in the cord group was significantly greater than Expasyl paste group (p<0.001). At all time intervals (7, 14, 28 days) the mean gingival recession in the cord group was significantly greater than Expasyl paste group (p<0.001) (Table 2). The average amount of gingival recession for the cord and paste were 0.14±0.07 and 0.03±0.04 mm at 28th days.

At 7 and 14 days after retraction, significant increase of GI were seen in the cord group than Expasyl paste group (p = 0.03, 0.014). But at days 28 GI returned to the base line in both groups (Table 3).

Exposing the subgingival margin of a preparation prior to taking an impression for indirect restorations maybe one of the most critical procedures for the dentist to perform (Nemetz and Seibly, 1990). This study is the first comparison of gingival retraction by means of a presaturated cord and a paste, which both of them have similar chemical agent (AlCl₃). Although, both 2 procedures had similar complete inflammatory healing in 28 days, they had significant differences in extent and duration of the inflammatory response and the permanent recession. Similar to previous histological studies (Hansen *et al.*, 1999; De Gennaro *et al.*, 1982; Akca *et al.*, 2006; Azzi *et al.*, 1983; Kopac *et al.*, 2002; Shaw *et al.*, 1980), both placement of the cord and the paste, leads to a reversible elevation in GI suggestive of an injury to the periodontium. But, the injury to the gingival tissues, based on the GI and gingival recession, was more severe in retraction with the cord than the paste. It could be due to the pressure applied during the cord application, which associated with the damage of the sulcular and junctional epithelium and underlying connective tissue.

The dentist prefers to perform gingival retraction before preparation of the tooth. The aim of this procedure is to prevent damage to the sulcular epithelium. Moreover, the epithelium will be more vulnerable to chemical trauma related to the amount of tissue damage and gingival recession might result (Tebrock, 1986). For these reasons, tooth preparations were made at the level of the free gingival margin to avoid tissue damage.

They recommend that cords should be soaked in the medicament solutions containing AlCl₃, Fe² (SO₄)₃ or epinephrine, uniformly for about 10 min. The cord (#1) employed in this study, owing to its nonshredding property, seems to be well suited to expose the gingival sulcus and improve access and visibility.

Table 2: Statistical evaluation of gingival recession in both groups

Recession/days	Mean	SD	SEM
Pair 1*			
CO/7	0.15	0.06	0.013
EX/7	0.07	0.06	0.014
Pair 2*			
CO/14	0.27	0.06	0.014
EX/14	0.11	0.06	0.015
Pair 3*			
CO/28	0.14	0.07	0.017
EX/28	0.03	0.05	0.011

CO: Cord; EX: Expasyl; (p<0.001) Statistically significant

Table 3: Evaluation of groups for inflammatory changes

Inflammation score	Score of time intervals (days)					
	7		14		28	
	EX	CO	EX	CO	EX	CO
0	12 (60)	5 (25)	20 (100)	14 (70)	20 (100)	20 (100)
1	8 (40)	14 (70)	6 (30)	---	---	---
2	1 (5)	---	---	---	---	---
3	---	---	---	---	---	---

CO: Cord; EX: Expasyl; The numbers in the brackets represented the frequency

In the present study, the width of the retracted sulcus of the presaturated retraction cord was significantly greater than that of the Expasyl paste, but both of them were more than critical sulcular width and effective enough. The average length of retracted sulcus in the paste group was similar to plain cord groups which had been reported by Bowles *et al.* (1991).

Feng *et al.* (2006) have reported that gingival retraction resulted in an elevation of the proinflammatory cytokine in gingival crevicular fluid which may lead to gingival recession even after clinical healing has occurred. According to our finding, effects of gingival retraction with Expasyl paste were much similar to those of plain cord which have been reported in the previous studies and retraction using Expasyl paste produced less gingival recession and inflammation than aluminum chloride presaturated cord, indicated the advantage of gentle tissue management which leads to better and prolong healing. In practice, it is clinically obvious when the thickness of adherent gingival was vulnerable.

We should acknowledge the limitation of the present study. The sample size in future studies should be larger to afford sufficient power to find other effects of retraction on thick or thin periodontium. Retraction with Expasyl paste is too expensive, although the simplicity of the method and no further need of local anesthesia make the procedure more acceptable.

CONCLUSION

The sulcular width of presaturated retraction cord January 5, 2009 was greater than Expasyl paste, but the

amount of retraction in both groups were effective enough. In compare with aluminum chloride presaturated cord, retraction by Expasyl paste accompany with less gingival recession and inflammation.

ACKNOWLEDGEMENT

The authors would like to thank Farzan institute for Research and Technology for technical assistance.

REFERENCES

- Akca, E.A., E. Yildirim and M. Dalkiz, 2006. Effects of different retraction medicaments on gingival tissue. Quint. Int., 37: 53-57.
- Azzi, R., T.F. Tsao, F.A. Carranza, Jr and E.B. Kenney, 1983. Comparative study of gingival retraction methods. J. Prosthet. Dent., 50: 561-565.
- Bowles, W.H., S.J. Tardy and A. Vahadi, 1991. Evaluation of new gingival retraction agent. Dent. Res., 70: 1447-1449.
- Csmpesz, F., J. Vag and A. Fazekas. 2003. *In vitro* kinetic study of absorbancy of retraction cords. J. Prosthet. Dent., 89: 45-49.
- De Gennaro, G.G., H.M. Landesman, J.E. Calhoun and J.T. Martinoff, 1982. A comparison of gingival inflammation related to retraction cords. J. Prosthet. Dent., 47: 84-86.
- Donovan, T.E. and W.W.L. Chee, 2004. Current concepts in gingival displacement. Dent. Clin. N. Am., 48: 433-444.
- Donovan, T.E., B.K. Gandara and H. Nemetz, 1985. Review and survey of medicaments used with gingival retraction cords. J. Prosthet. Dent., 53: 525-531.
- Fazekas, A., F. Csmpesz, Z.S. Csabai and J. Vagx, 2002. Effects of pre-soaked retraction cords on the microcirculation of the human gingival margin. Oper. Dent., 27: 343-348.
- Feng, J., S. Weiner and H. Aboyoussef, 2006. The effect of gingival retraction procedures on periodontal indices and crevicular fluid cytokine levels: A pilot study. J. Prosthodont., 15: 108-112.
- Ferrary, M.G., M. Coagidaco and C. Ercoli, 1996. Tissue management with a new gingival retraction material: A preliminary clinical report. J. Prosthet. Dent., 75: 242-247.
- Hansen, P.A., D.E. Tira and J. Barlo, 1999. Current methods of finish-line exposure by practicing prosthodontists. J. Prosthodont., 8: 163-170.
- Kopac, I., E. Cvetko and M. Ljubo, 2002. Gingival inflammatory response induced by chemical retraction agents in beagle dogs. Int. J. Prosthodont., 15: 14-19.
- Laufer, B., H. Bahara and H.S. Cardash, 1994. The linear Accuracy of impression and stone Dies as affected by the thickness of the impression margin. Int. J. Prosthodont., 7: 247-252.
- Laufer, B., H. Baharav, Y. Ganor and H.S. Cardash, 1996. The effect of marginal thickness on the distortion of different impression materials. J. Prosthet. Dent., 76: 466-471.
- Laufer, B.Z., Y.B. Langer and H.S. Cardash, 1997. The closure of gingival crevice following gingival retraction for impression making. J. Oral. Rehabil., 24: 629-635.
- Nemetz, E.H. and W. Seibly, 1990. The use of chemical agents in gingival retraction. Gen. Dent., 38: 104-108.
- Rateitschak, K.H., 1989. Color Atlas of Dental Medicine Periodontology.
- Ruel, J., P.J. Schuessler, K. Malament and D. Mori, 1980. Effect of retraction procedures on the periodontium in humans. J. Prosthet. Dent., 44: 508.
- Shaw, D.H., R.F. Krejci and D.M. Cohen, 1980. Retraction cords with Aluminum chloride: Effect on the gingival. Oper. Dent., 5: 138-141.
- Tebrock, O.T., 1986. Tissue retraction for esthetic ceramometal crowns. J. Prosthet. Dent., 55: 21-23.