

## Cryosurgical Treatment of Two Exophytic Lesions of Oral Mucosa

<sup>1</sup>Farid Abbasi, <sup>1</sup>Azar Darbandy, <sup>2</sup>Roza Haghgoo and <sup>3</sup>Hassan Semyari

<sup>1</sup>Department of Oral Medicine, <sup>2</sup>Department of Pediatric Dentistry,

<sup>3</sup>Department of Periodontology, Dental School, Shahed University, Tehran, Iran

**Abstract:** Exophytic lesions are papillomatous, verrucous, popular, nodular, dome shaped, polypoid and bosselated that can be treated by cryotherapy. The aim of this study was to evaluate effectiveness of cryotherapy on squamous papilloma and fibroma. Total 20 squamous papilloma and fibroma in 20 patients aged 20-65 year were treated. Each lesion was frozen with nitrogen oxide for 20-30 sec and the patients were examined 1 week and 2 weeks after treatment. Finally the data was analyzed with paired t test. The lesions in 17 patients were recovered completely after 1 week. The lesions in 3 patients have been become smaller. There was significantly difference between diameter of the lesions before and after treatment ( $p < 0.05$ ). Results of this study showed cryotherapy can be applied successfully in treatment of fibroma and squamous papilloma.

**Key words:** Cryotherapy, papilloma, fibroma, treatment, exophytic lesions, oral mucosa

### INTRODUCTION

Exophytic lesions are papillomatous, verrucous, popular, nodular, dome shaped, polypoid and bosselated. As a general rule, exophytic lesions with a papillomatous or verrucous shape originate in the surface epithelium (e.g., Papillomas) whereas those with a smoothly contoured shape originate in the deeper tissue and are beneath and separate from the stratified squamous epithelium (e.g., fibroma) (Wood and Goaz, 1997).

Squamous papilloma is a benign proliferation whose surface may vary from cauliflower-like to finger like in appearance and although it is generally a pedunculated lesion, it may arise from a sessile base. The most common sites of occurrence appear to be the tongue and palatal complex, followed by the buccal mucosa, gingiva and lips (McDonald, 2004).

Fibroma is the most common benign soft tissue tumor found in the oral cavity. It is characteristically a dome shaped lesion with a sessile base and a smooth surface that is usually the color of the surrounding mucosa. It may vary from firm to flaccid in texture. The most common location is the buccal mucosa along the bite line (Neville *et al.*, 2002).

Squamous papilloma and fibroma are treated by conservative surgical excision.

Cryotherapy, is a therapeutical method successfully used for many cutaneous conditions. The oral mucosa because of its characteristics of humidity and smoothness, is an ideal site for this technique. It shows a very good esthetic result (Ishida and Ramos-e-Silva,

1998). Cryotherapy is the deliberate destruction of tissue by application of extreme cold (Farah and Savage, 2006).

Studies on oral cryotherapy have been shown that after the lesions were frozen, healing was uneventful and tissue regeneration resulted (Tal, 1992).

Extremely limited information is available on application of cryosurgery in exophytic lesions. The purpose of this study was to evaluate effect of cryosurgery on squamous papilloma and fibroma.

### MATERIALS AND METHODS

Design of this study was clinical trial. This study was conducted at the Shahed University-Tehran-Iran in January and February 2007. It included 20 patients (12 female and 8 male) aged 20-65 years who manifested squamous papilloma or fibroma in clinical examination. Participants were healthy and none of them had received previous treatment for these lesions. Written informed consent was obtained from the patients. Eleven lesions located on the tongue (55%), 6 cases on the hard palate (30%) and 3 cases on the lip (15%). Lesions ranged from 2-10 mm in diameter. There were 13 fibroma (65%) and 7 squamous papilloma (35%). All treatments were carried out by a specialist in oral medicine and under local anesthesia (lidocaine 2% contained epinephrine 1/100000). A probe that closely corresponded to the size of the lesion was selected and the area was frozen with nitrogen oxide 20-30 sec and necrosis was seen around the probe. Each lesion was treated in an appointment. Patients were examined 1 week

and 2 weeks after treatment and recovery of the lesions was evaluated. Finally, the data was analyzed with paired t test.

## RESULTS AND DISCUSSION

All patients were examined 1 week and 2 weeks after treatment. The lesions in 17 patients were recovered completely after 1 week (Fig. 1 and 2). The lesions in 3 patients have been become smaller but not 0 in diameter, these lesions were fibroma. These patients were treated again and were evaluated after 1 week. 2 patients were recovered completely and in 1 case no change was seen. There was significantly difference between diameter of the lesions before and after treatment ( $p < 0.05$ ).

Squamous papilloma and fibroma are exophytic lesion that are usually treated by surgical procedure successfully. These lesions can be treated by cryotherapy. Cryotherapy is a simple to use weakly invasive technique provoking only moderate complications in the treatment of certain oral lesions (Barrellier *et al.*, 1992).

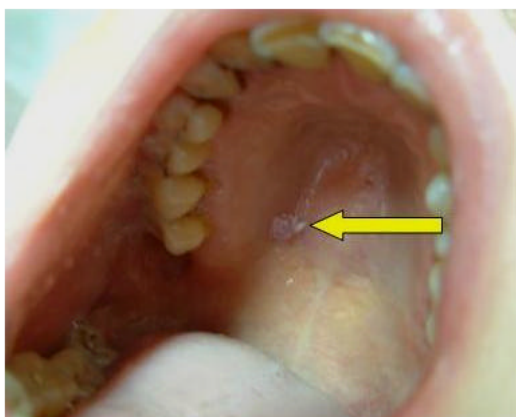


Fig. 1: Papilloma before treatment

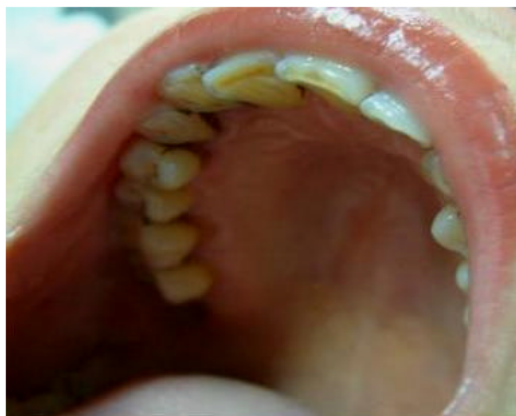

Fig. 2: Papilloma after treatment

The aim of this study was to evaluate effectiveness of cryotherapy on treatment of squamous papilloma and fibroma. Results of this study showed that 85% of lesions were treated 1 week after treatment and 10% after 2 weeks.

Findings of this study is coincide with Tal's study. The patients in Tal's study were recovered after 3 weeks but 85% of the patients in our study were treated after 1 week. In both study, recovery occurred without scar formation and secondary inflammation and bleeding. Freezing time in these 2 studies was different; 40 sec in Tal's study and 20-30 sec in our study (Tal, 1992).

Ishida found that cryotherapy is a safe and inexpensive treatment for oral lesion. He reported edem, vesicle after treatment. He used liquid nitrogen alone or associated with other other surgical methods in various types of oral lesions and these complications can be related to accompanying surgical methods with cryotherapy (Ishida and Ramos-e-Silva, 1998).

Yeh (2000) evaluated effect of cryotherapy on mucocel, lukoplakia, hemangioma and lichen planus and labial fibroma. He found that cryotherapy is a simple and safe method. He used liquid nitrogen for treatment and this agent is more effective in eradication of relatively small oral lesions.

## CONCLUSION

Based on the results of this study cryotherapy is a simple and easy method that can be applied successfully in treatment of fibroma and squamous papilloma.

## REFERENCES

- Barrellier, P., M.Y. Louis and E. Babin, 1992. The use of cryotherapy in oral pathology. *Rev. Stomatol. Chir. Maxillofac.*, 93: 345-348.
- Farah, C.S. and N.W. Savage, 2006. Cryotherapy for treatment of oral lesions. *Aus. Dent. J.*, 51: 2-5.
- Ishida, C.E. and M. Ramos-e-Silva, 1998. Cryosurgery in oral lesions. *Int. J. Dermatol.*, 37: 283-285.
- McDonald, R.E., Avery and J.A. Dean, 2004. *Dentistry for Child and Adolescent*. 8th Edn. Mosby Co, Chap 8: 150-151.
- Neville, B.W., D.D. Damm and C.M. Allen, 2002. *Oral and Maxillofacial Pathology*. 2th Edn. Saunder Co., Chap 10: 316.
- Tal, H., 1992. Cryosurgery treatment of hemangioma of the lip. *Oral. Surg. Oral. Med. Oral. Pathol.*, 73: 650-654.
- Wood, N.K. and P.W. Goaz, 1997. *Oral Maxillofacial Lesions*. 5th Edn. Mosby Co., Chap, 10: 130.
- Yeh, C.J., 2000. Simple cryosurgical treatment of the oral melanotic macule. *Oral. Surg. Oral. Med. Oral. Pathol.*, 90: 12-13.