

## Non-Familial Juvenile Colloid Milium: A Case Report from Iran

<sup>1</sup>Hajheydari Zohreh and <sup>2</sup>Ghasemi Maryam

<sup>1</sup>Department of Dermatology,

Department of Pathology, Mazndaran University of Medical Science,

Boo-Ali Sina Hospital, Sari, Iran

**Abstract:** Juvenile Colloid Milium (JCM) is an exceedingly rare degenerative condition of skin that begins prior to puberty. We report a 22-years-old girl with non-familial JCM. Histopathologically, superficial dermal deposits of colloid material in direct contact with the thin epidermis of her lesional skin biopsy were observed.

**Key words:** Colloid milium, juvenile, no-familial, histopathology, epidermics, skin biopsy

### INTRODUCTION

Colloid milium is a degenerative change with unidentifiable causes, characterized clinically by the development of yellowish, translucent papules or plaques on light-exposed and histologically by the presence of colloid in the dermis.

**Case report:** A 22-years-old girl referred to our dermatology department with numerous small papules on her face. She had these papules since 10 years ago, that gradually became larger and exacerbated in the summer. There was no history of previous utility of bleaching cream. The patient has no family history. Her parents were non-consanguineous. Physical examination revealed a type III skin with numerous isolated or confluent yellowish-colored papules, measuring 1 to 2 mm in diameter on the nose (Fig. 1). There were no other signs.

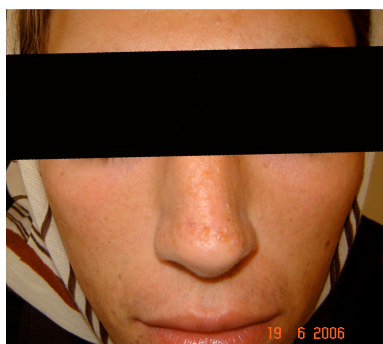

Fig. 1: Numerous, small, yellowish papules, on the nose

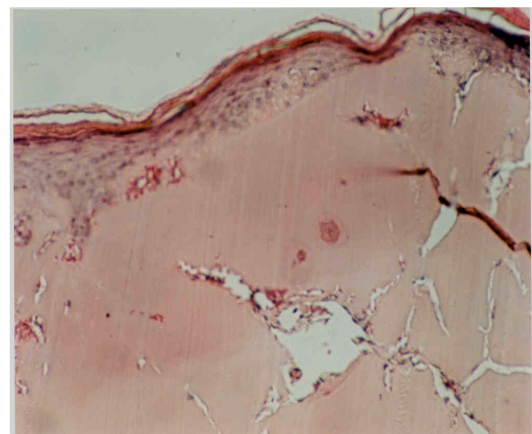


Fig. 2: There is a homogenous fissured mass of colloid in upper dermis, contiguous with basal layer of thin overlying epidermis haematoxylin and Eosin, original magnification X 100

A lesional skin biopsy was taken from the nose. Histological examination of H and E stained slide showed well-defined homogenous fissured masses of amorphous eosinophilic material with scant fibroblast in the upper dermis. There was no elastosis of dermis (Fig. 2). This amorphous material was strongly positive with periodic acid-Schiff (Fig. 3) but negative with Congo red staining for amyloid.

These clinicopathologic features, as described above were consistent with Juvenile colloid milium.

**Correspondence Author:** Hajheydari Zohreh, Department of Dermatology and Venorology, Mazandaran University of Medical Sciences, Boo-Ali Sina Hospital, Sari, Iran

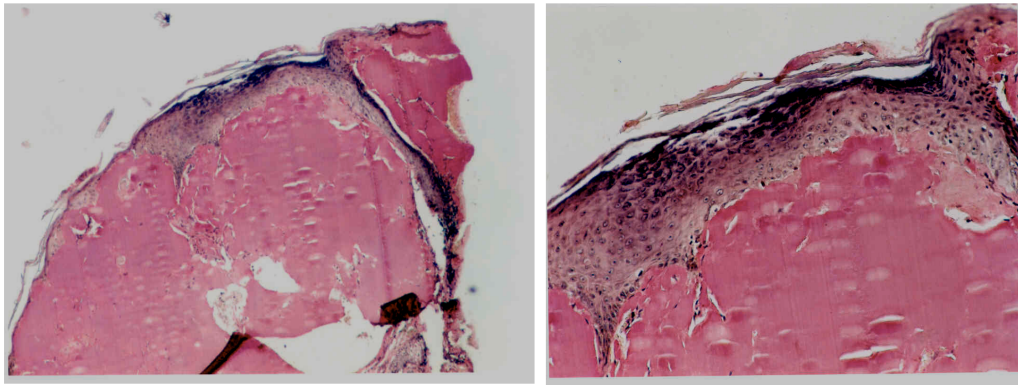


Fig. 3: Periodic acid-Schiff positively in the colloid material; A: Original magnification X 40; B: Original magnification X 100

## RESULTS AND DISCUSSION

There are 3 types of colloid degeneration of the skin: Juvenile, adult and nodular (Burrows Covell, 2005; Chowdhury *et al.*, 2000). Juvenile type, a very rare form of CM, has its onset before puberty and shows numerous round yellowish-brown waxy papules distributed mainly on sun-exposed area particularly the face (Ekekei *et al.*, 2005). The cause of JCM is not known. In nearly half of the reported cases there is a positive family history so as, some authors suggest an autosomal recessive inheritance. Some times, it is preceded by moderate to severe sunburn (Denguezli *et al.*, 2002). Also there is some reported sporadic form (Ekekei *et al.*, 2005). Adult type, the most common form of colloid milium, has its onset in the age of 30-50 years that clinically is indistinguishable from juvenile type. It is certainly occurs in fair-skinned outdoor workers (Muscardin *et al.*, 2000). The third form known as nodular type consist of isolated or multiple plaques or nodules 0.5-5 cm in diameter mostly located on the face but occasionally on the trunk and extremities (Handfield-Jones *et al.*, 1992). These forms can be distinguished histologically. The juvenile form shows dermal well defined masses of fissured eosinophilic material with some fibroblasts or small blood vessels in direct contact with basal layer of flattened epidermis. The colloid is derived from degenerated keratinocytes. Therefore, immunohistochemically positive with anticytokeratin. Histochemically the colloid is PAS positive but negative or weakly positive with Congo red staining for amyloid. However in adult type, the colloid material is derived from degenerated elastic fibers of dermis and separated by a Grenz zone from overlying epidermis. Furthermore prolonged phenol exposure, contact with mineral oils and hydroquinone were reported to be the other causing agents of colloid millium (Muscardin *et al.*, 2000;

Findly *et al.*, 1975; Philips *et al.*, 1986). Present patient suffers from a papular lesion on the face with the onset prior to puberty for which a long period was treated the wrong diagnosis such as acne vulgaris. We proved its correct diagnosis histologically as JCM. Because this case has neither positive family history nor consanguinity of her parents, is a non-familial form of JCM, with aggravation in the summer. According to present observation and previous literature claim that sunshine play an important role in the etiology of this disease<sup>3</sup>, we advised her to use proper sunscreen cream. Colloid milium is chronic disease, difficult to treat. There are some treatment modalities including dermabrasion, diathermy, cryotherapy and long-pulsed Er: Yag Laser (Ekekei *et al.*, 2005; Ammirati *et al.*, 2002).

## REFERENCES

- Ammirati, C.T., J.M. Giancola and G.J. Hruza, 2002. Adult-onset facial colloid milium successfully treated with the long-pulsed Er: Yag laser. *Dermatol. Surg.*, 28: 780.
- Burrows, N.P. and C.R. Lovell, 2005. Disorder of Connective Tissue. In: Burns T., S. Breathnach, N. Cox and C. Griffiths (Eds.), *Text Book of Dermatology* (7th Edn.), Vol. 3. Oxford: Blackwell Scientific, 46: 67-68.
- Chowdhury, M.M.U., S. Blackford and S. Williams, 2000. Juvenile colloid milium associated with ligneous conjunctivitis. Report of a case and review of the literature. *Clin. Exp. Dermatol.*, 25: 138-140.
- Denguezli, M., N. Ghariani and M. Kourda *et al.*, 2002. Juvenile colloid milium. *Ann. Dermatol. Venereal.*, 129: 1386-88.
- Ekekei, T.R., A. Koslu and D. Sakiz, 2002. Juvenile colloid milium: A case report. *Eur. Acad. Dermatol. Venereal.*, 19: 355-356.

- Findly, G.H., J.G.L. Morrison and I.W. Simsom, 1975. Exogenous ochronosis and pigmented colloid milium from hyperquinone bleaching creams. *Br. J. Dermatol.*, 93: 613-22.
- Handfield-Jones, S.E., D.J. Atherton and M.M. Black *et al.*, 1992. Juvenile colloid milium: clinical, histological and ultrastructural features. *J. Cutan Pathol.*, 19: 434-38.
- Muscardin, L.M., M. Bellocci and L. Balus, 2000. Papuloverrucous colloid milium: On occupational variant. *Br. J. Dermatol.*, 143: 884-887.
- Philips, J.L., C. Isaacson and H. Carman, 1986. Ochronosis in black South Africans who used skin lighteners. *Am. J. Dermatopathol.*, 8: 14-21.