

Report and Review of Spinal Cord Tumors

¹M. Pourissa, ²S. Refahi and ²M.H. Dehghan

¹Tabriz University of Medical Sciences, Tabriz, Iran

²Ardebil University of Medical Sciences, Ardebil, Iran

Abstract: Spinal tumors are uncommon lesions but may cause significant morbidity in terms of limb dysfunction. We retrospectively reviewed the medical records of 90 patients who hospitalized on at our institution since January 2003-December 2006. The purpose of this study was to determine the usefulness of Magnetic Resonance Imaging (MRI) in localizing and detecting types of the spinal tumors in 50 patients with spinal tumors operated at the Imam Khomeini Hospital, Tabriz, Iran. We describe the most common spinal tumors in detail. In general, intradural extramedullary lesions are the most common with metastasis being the most frequent. Intrathecal lesions are rare. Finally we illustrate that use of magnetic resonance imaging can be useful to recognizing of spinal tumors, specially after administration of a contrast media by sensitivity of 94%.

Key words: Spinal tumors, magnetic resonance imaging, pathology

INTRODUCTION

Spinal tumors are uncommon lesions and affect only a minority of the population. However, these lesions can cause significant morbidity in terms of the limb dysfunction and can be associated with mortality as well. In establishing the differential diagnosis for a spinal lesion, location in the most important feature. Magnetic Resonance Imaging (MRI), which plays the central role in the imaging of spinal tumors, easily allows tumors to be classified as extradural, intradural-extramedullary or intramedullary (Van Goethem *et al.*, 2004). Technical advances in imaging technique, magnetic resonance imaging and surgical procedures have brought about significant better clinical results in the last 2 decades. Exact localization of the spinal tumors is particularly important for differential diagnosis and surgery. Therefore, it was attempted to evaluate the diagnostic usefulness of MRI in localizing and detecting types of the spinal tumors exactly. Also, the authors describe the most common types of spinal tumors in 50 patients with spinal tumors admitted and operated on between January 2003 and Desember 2007 at the Imam Khomeini Hospital, Tabriz, Iran.

MATERIALS AND METHODS

We retrospectively reviewed medical records of 90 patients who were hospitalized for surgical treatment of known spinal tumors between January 2003 and December 2006 during the past 4 years, within the Department of

neurosurgery at the Imam Khomeini Hospital, Tabriz, northwestern Iran. Patients had not exact medical records of MRI and pathologic reports excluded from the study. 50 patients among total patients were undergo operative surgery and had completed medical information. All MRI examinations were performed by a dedicated radiologist with 15 years of experience using a Hitachi MRI unit with 0.3 tesla magnet. Pathologic reports were reviewed by a pathologist with 10 years of experience. Pathologic reports were obtained from post operative specimens for all patients. The frequency and types of tumors and also comparison of the preoperative MRI reports and final pathologic diagnoses was performed and data was analyzed. The MRI sensitivity was determined for predicting the presence of spinal tumors and their types.

RESULTS

In this study most of patients were in the fourth, fifth and sixth decades of life (age rang, 25-70 years; mean age, 45 years). Our results demonstrate the most frequent tumors was metastases 14/50 (28%), closely followed by meningiomas 13/50 (26%) and schwannomas 10/50 (20%). In 27/50 (54%) patients tumors were found to be completely intradural extramedullary, in 14/50 (28%) extramedullary, in 6/50 (12%) extradural and in 3/50 (6%) intrathecal during MRI examination. Number, location of tumors showed in (Table 1). Comparison of the preoperative MR images and final pathologic diagnoses revealed in 41/50 (82%) patients, MRI without injection an intravenous contrast agent was able to diagnose the

Table1: Summary of patients with spinal tumors

Tumor name	Number	Location
Metastasis	14	Extradural
Meningiomas	13	Intradural extramedullary
Schwannoma	10	Intradural extramedullary
Neurofibromatosis	3	Intradural extramedullary
Lymphoma	4	Extradural
Aneurismal bone cyst	1	Extradural
Myeloma	1	Extradural
Astrocytoma	1	Intradural extramedullary
Ependymoma	3	Intrathecal

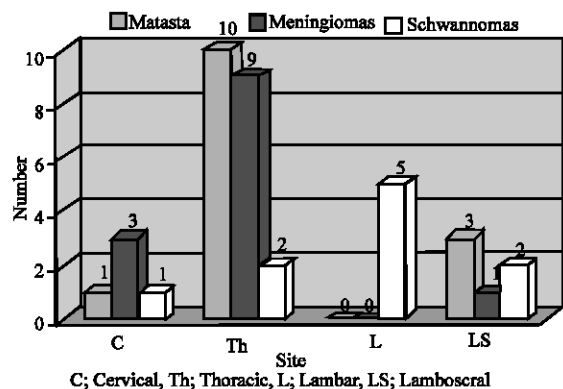


Fig. 1: The distribution of spinal tumors site

types of spinal tumors. However, MRI after intravenous injection of contrast media was able to diagnose the types of tumors in 47/50 (94%) of cases. The most frequent site of spinal tumors was in the thoracic region. The lumbosacral region was the next most frequent sites, followed by the lumbar and cervical regions. The distribution of tumors according to site of spinal tumors is shown in (Fig. 1). Finally identification of location spinal tumors was correct in 100% cases (sensitivity of 100%).

DISCUSSION

Intraspinal intradural extramedullary tumors are relatively frequent neoplasms (Albanese and Platania, 2002). Meningiomas and nerve sheath tumors (schwannomas and neurofibromas) make up for about 90% of all intradural extramedullary tumors. Nerve sheath tumors are the most frequent intraspinal mass lesion, accounting for 30% of all cases (A). In the current study, 27/50 (54%) of tumors were intradural extramedullary and 26/27 (96.3%) of tumors consist meningiomas and nerve sheath tumors. Spinal schwannomas are mostly benign, intra-dural extramedullary tumors. On T2-weighted images, the signal intensity appeared significantly hyperintense and heterogeneous for schwannomas (2). We observed 10 cases of schwannomas that were located at the

lumbosacral levels in two cases, at the lumbar in the 5 cases, at the thoracic in the two cases and at the cervical in the one case. All of schwannomas were intradural extramedullary. Spinal canal obstruction presented in the all cases. MR images without contrast media allowed diagnosis of schwannomas with a sensitivity of 9/10 (90%). Spinal meningioma is a benign lesion that commonly occurs in women of middle age. It accounts for approximately 25-46% of spinal tumors. Spinal meningioma arises from cap cells of the arachnoid membrane and originates in proximity to nerve roots. Location in approximately 3-15% of all cases of spinal meningioma is extradural and it is almost always associated with an intradural component, although this connection can not always be confirmed (Gezen *et al.*, 2000). These tumors occasionally arise in the spine, typically the thoracic level (Nicolas *et al.*, 2007). In general 80% of meningiomas are found in the thoracic region, 15% are cervical and 5% are lumbosacral. In the thoracic region most meningiomas are posterolateral. Spinal meningiomas are iso-to hyperintense T1WI and slightly hyperintense on T2WI (Van Goethem *et al.*, 2004). In our report, 9/13 (69.2%) meningioma were located in the thoracic region and all of them were located posterolateral. The incidence of thoracic location was reported by Levy *et al.* (1982) as 75%, by Namer *et al.* (1987) as 66% and by Roux *et al.* (1996) as 79.5%. The vertebral column is the most common site for bony metastases, with an incidence of 30-70% in patients with metastatic neoplasms. Spinal metastases can occur in 3 location: Extradural, Intradural Extramedullary (IDEM) and Intramedullary (IM). More than 98% of spinal metastases are extradural because the dura mater provides a relative barrier for metastatic disease, IDEM and IM disease account less than 1% of spinal metastatic disease (Ecker *et al.*, 2005). On the MR imaging most metastases are hypointense on T1WI. On T2WI they can be either dark (sclerotic) or more frequently show high signal. Marked enhancement after contrast administration is the rule (Baur *et al.*, 2002; Spuentrup *et al.*, 2001). MRI was able to recognize types of metastases in 13/14 (92.85%). In general, extradural lesions constitute the most frequent group of spinal tumors. The malignant extradural tumors include lymphoma, myeloma chordoma, Ewing sarcoma, chondrosarcoma and metastasis. The most frequent benign extradural tumors are hemangioma, osteoid osteoma, osteoblastoma, Aneurismal Bone Cyst (ABC), giant cell tumor, granuloma and osteochondroma. Lymphoma is not led to a single spinal compartment. Spinal cord involvement is usually metastatic

(Dickman *et al.*, 2006). Lymphoma demonstrates solid enhancement adjacent high T2 signal intensity consistent edema. Cord enlargement is not as severe with other intramedullary neoplasms (Bloomer *et al.*, 2006). We documented one case of myeloma and four cases of lymphoma pathologically. Lymphomas comprise the majority of the extradural tumors. The common MRI finding was a solid enhanced mass that was hyperintense on T2-weighted images. The majority of lymphoma located on the lumbosacral region. MR imaging was not able to detect half of lymphoma. No case of myeloma was detected by MRI in this report. Aneurismal Bone Cysts (ABCs) are nonneoplastic processes characterized by an expansile and aggressive bone lesion with multiloculated blood spaces. They may arise at a site of prior spinal trauma or may be induced by anomalous vascular process (Kransdorf and Sweet, 1995). Aneurismal bone cysts are most common in the lumbar spine, followed by the cervical spine (22%). Spinal ABCs are located in the posterior elements in 60% and in the vertebral body in 40% of cases. Lesions tend to involve adjacent vertebrae and can cross the intervertebral disc space to involve 3 or more contiguous vertebrae (Rai and Collins, 2005). In this approach only one of patients showed aneurismal bone cysts in pathological finding. MRI feature did not recognize it. MRI demonstrated an extradural mass in the C₅ vertebral body without any cystic lesion.

Astrocytomas account for approximately 30% of intramedullary tumors. More than half of all astrocytomas are seen in the thoracic region, usually in the upper thoracic cord. They usually involve multiple segments. Magnetic resonance imaging of astrocytomas may be radiographically indistinguishable from ependymomas. Full diameter cord involvement and homogenous high T2 signal intensity favor the diagnosis of astrocytoma. Most astrocytoma present as ill-defined diffuse fusiform enlargement of the cord at the time of diagnosis. They are isointense to slightly hypointense on T1WIs and hyperintense on T2WIs (Van Goethem *et al.*, 2004). In current study only one case was astrocytoma according to pathological results. In MR images reported as an hypodense intradural extramedullary mass at the lumbosacral. MRI can not able to detect type of tumor. Ependymomas represent approximately 60% of all glial-based tumors of the spinal cord and filum terminale. Spinal ependymomas are slow-growing tumors that arise from ependymal cells lining the central canal or from ependymal rests present in the filum terminale or sacral regions. They are usually well circumscribed and do not infiltrate adjacent cord tissue. Cyst formation and hemorrhage is common, especially at the tumor margins. Most of the ependymomas occur in the lumbosacral region but any

segment of the spinal cord may be involved (Yokota *et al.*, 2003). Ependymomas commonly are hyperintense on T2WI (Van Goethem *et al.*, 2004). In our study three cases of patients had ependymoma. Cyst formation showed only in one case. None of cases did not demonstrate hemorrhage. All of cases of ependymomas localized in the lumbar region. MRI feature were consistent with pathological finding in 100% cases.

CONCLUSION

In this report, 50 of spinal tumors have been reviewed. The most common tumors were metastases, meningiomas and schwannomas. Magnetic resonance imaging after injection a contrast media is considered the best neuroimaging technique for diagnosis of types of spinal tumors by sensitivity of 94%.

REFERENCES

- Albanese, V. and N. Platania, 2002. Spinal intradural extramedullary tumors. Personal experience. *J. Neur. Sci.*, 46: 18-24.
- Baur, A., O. Dietrich and M. Reiser, 2002. Diffusion-weighted imaging of the spinal column. *Neuroimag. Clin. N. Am.*, 12: 147-60.
- Bloomer, C.W., A. Ackerman and R.G. Bhatia, 2006. Imaging for spine tumors and new applications. *Top. Magn. Reson. Imag.*, 17: 69-87.
- De Verdelhan, O., C. Haegelen, B. Carsin-Nicol, L. Riffaud, S.E. Amlashi and G. Brassier *et al.*, 2005. MR imaging features of spinal schwannomas and meningiomas. *J. Neuroradiol.*, 32: 42-49.
- Dickman, C.A., M.G. Fehlings and Z.L. Gokaslan, 2006. In: Dickman CA, Fehlings MG, Gokaslan ZL, (Eds.), *Spinal Cord and Spinal Column Tumors: Principles and Practice*. New York, NY: Thieme., pp: 145-176.
- Ecker, R.D., T. Endo, N.M. Wetten and W.E. Krauss, 2005. Diagnosis and treatment of vertebral column metastases. *Mayo. Clin. Proc.*, 80: 1177-1186.
- Gezen, F., S. Kahraman, Z. Canakci and A. Beduk, 2000. Review of 36 cases of spinal cord meningioma. *Spine*, 25: 727-731.
- Kransdorf, M.J. and DE. Sweet, 1995. Aneurysmal bone cyst: Concept, controversy, clinical presentation and imaging. *AJR. Am. J. Roentgenol.*, 164: 573-580.
- Levy, W.J., J. Bay and D. Dohn, 1982. Spinal cord meningioma. *J. Neurosurg.*, 57: 804-812.
- Namer, I.J., M.N. Pamir, K. Benli, S. Saglam and A. Erben, 1987. Spinal meningiomas. *Neurochirurgia (Stuttg)*, 30: 11-15.

- Nicolas, M.M., R. Kaakaji, E.J. Russell, D.V. De Frias and R. Nayar, 2007. Extradural spinal meningioma as a source of plasmacytoid cells. A case report. *Acta. Cytol.*, 51: 68-72.
- Rai, A.T. and J.J. Collins, 2005. Percutaneous treatment of pediatric aneurysmal bone cyst at C1: A minimally invasive alternative: A case report. *AJNR Am. J. Neuroradiol.*, 26: 30-33.
- Roux, F.X., F. Nataf, M. Pinaudeau, G. Borne, B. Devaux and J.F. Meder, 1996. Intraspinal meningiomas: Review of 54 cases with discussion of poor prognosis factors and modern therapeutic management. *Surg. Neurol.*, 46: 458-464.
- Spuentrup, E., A. Buecker, G. Adam, J.J. Van Vaals and R.W. Guenther, 2001. Diffusion-weighted MR imaging for differentiation of benign fracture edema and tumor infiltration of the vertebral body. *AJR. Am. J. Roentgenol.*, 176: 351-388.
- Van Goethem, J.W., L. van den Hauwe, O. Ozsarlak, A.M. De Schepper and P.M. Parizel, 2004. Spinal tumors. *Eur J. Radiol.*, 50: 159-176.
- Yokota, T., T. Tachizawa, K. Fukino, A. Tetamoto, J. Kouno, K. Matsumoto and M.A. Emi, 2003. Family with spinal anaplastic ependymoma: Evidence of loss of chromosome 22q in tumor. *J. Hum. Genet.*, 48: 598-602.