

## The Morphological Observations of Some Lingual Papillae in Camelus Dromedaries Embryoes

<sup>1</sup>E. Salehi, <sup>2</sup>I. Pousti, <sup>1</sup>H. Gilanpoor and <sup>2</sup>M. Adibmoradi

<sup>1</sup>Department of Anatomy, Faculty of Specialized Veterinary Sciences, Science and Research Campus, Islamic Azad University, Tehran, Iran

<sup>2</sup>Department of Basis of Sciences, Faculty of Veterinary, Tehran University, Iran

---

**Abstract:** This study was carried out to investigate the morphological development of the tongue in the foetal stage of camelus dromedaries by light microscopy. In foetuses of about 60 days, the tongue tissues showed thickening of the epithelium into about 4-6 layers of cells. In foetuses of about 75 days, mesenchymal tissue was observed under the epithelium. Rudiments of some papillae were observed at this time. Collagenous fibre and blood vessels were scant in the lamina propria. In the 90 days old foetuses, there was further differentiation of the epithelium rudiments into some papillae and this continued to mature until in foetuses of about 105 days, were early rudiments of taste buds were observed and in 120 days old foetuses taste buds were developed well and taste buds cell were recognizable.

**Key words:** Development, lingual papilla, camelus dromedarius, embryo, taste bud, tongue, growth

---

### INTRODUCTION

The surface anatomy and histology of the adult tongue of domestic animals and its papillae is described in numerous textbooks of Histology (Fawcett and Raviola, 1994; Eurell *et al.*, 2006). Numerous research studies investigated morphogenesis of lingual papillae in various animal species (Alpin *et al.*, 1989; Tichy, 1992; Fujimoto *et al.*, 1993; Iwasaki *et al.*, 1996a; Kulawik, 2005a, b) and human (Witt and Reutter, 1997). The available reports were entirely concerned with adult structures of the tongue and papillae much less has been written about the prenatal development of the lingual papillae in camel.

This research described the light microscopic features of the development of the lingual papillae at the foetal stage in the one-humped camel (*Camellus dromedaries*), an important breed of camel in Iran. The study will also add to the existing information on the morphogenesis of the tongue in camels.

### MATERIALS AND METHODS

Tongues used for this study were obtained from 25 foetuses (5 specimen from each month). Camel uteruses were gathered from slaughter house in yazd province after dissecting the uteruses, the age of

foetuses were measured by crl formula (using crown-to-rump length), (age of foetus) =  $cr1 + 23.9/336$ , according to McGeady *et al.* (2006). The tongue tissues were fixed in Bouin's fluid, dehydrated in graded series of ethanol, cleared in xylene and embedded in paraffin wax. The blocks of tissues of tongue from apex, middle and root of the tongue were sectioned in transverse and longitudinal planes of the dorsum of the tongue. The slides were stained with hematoxylin and eosin. Selected sections were photographed with photomicroscope and the observations captured on a Laptop Computer. The morphological features were noted.

### RESULTS AND DISCUSSION

In the foetuses of about 60 days old, the sections taken from the dorsum of the apex and the body of tongue was covered by 4-6 layers of epithelial cells. The cells at the basal layer have large oval or round nuclei, while the apical cells consisted of lower cells, their nuclei being flattened. A well defined basement membrane was apparent.

Underlying it is the mesenchymal tissue with cells having oval nuclei and some amount of cytoplasm (Fig. 1). Some of the tongues of the foetuses of about 60 days old showed epithelial thickenings on the dorsum and in the apex of the tongue, the highest concentration

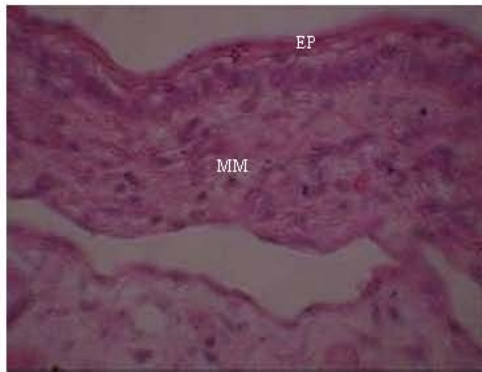


Fig. 1: Sixty days epithelial thickening (Ep) mesenchyme (MM), H and E x480

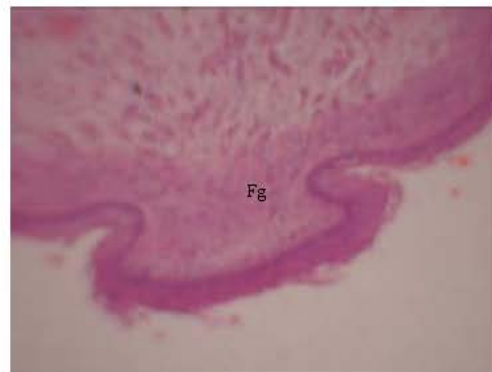


Fig. 3: Ninety days developing fungiform papillae, H and E x120

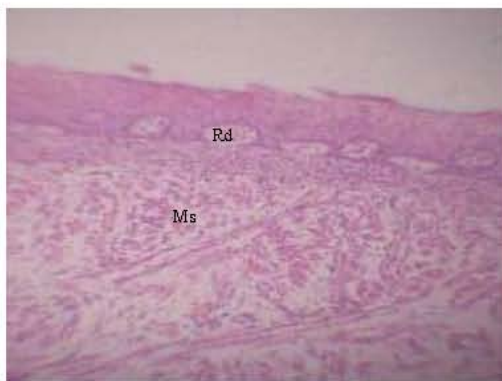


Fig. 2: Seventy five days of papillae (Rd), muscle cells (Ms), H and E x100

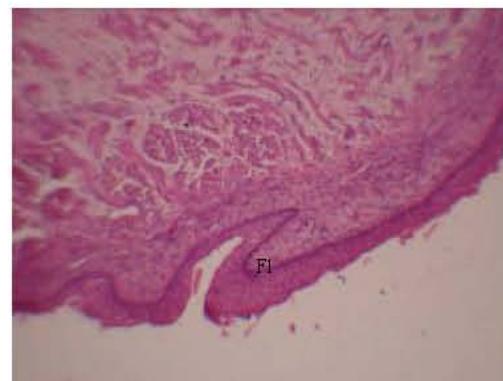


Fig. 4: Ninety days developing filiform papillae, H and E x120

being at the apex of the tongue. These thickenings probably were early rudiments of some lingual papillae.

In the fetuses of about 75 days old, there was further maturation of the epithelium. The dorsum of the apex, the body and root of the tongue showed rudiments of filiform and fungiform papillae, which was quite apparent. The arrangement of the rudiments of filiform papillae is similar to the distribution of epithelial thickenings (Fig. 2). The epithelial thickenings showed that cells are in about 10-12 layers, with the basement membrane very apparent, which rested on well defined lamina propria. The lamina propria of the mucous membrane formed protrusions, constituting the connective tissue core of the developing lingual papillae. In the fetuses of about 90 days old, there was further maturation of the papillae; primordial of filiform, vallate and fungiform were very apparent. There were marked differences from the previous age group. Collagenous fibres and blood vessels were present in the lamina propria (Fig. 3-5). The vallate papillae showed maturation and folding of the epithelium.

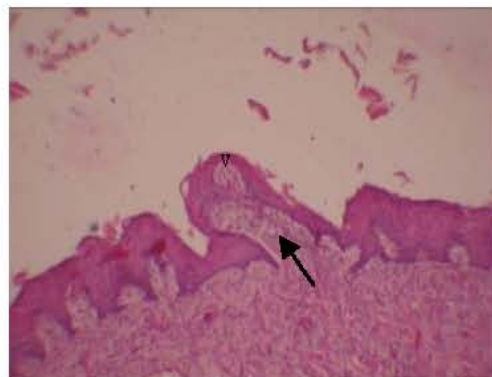


Fig. 5: Ninety days developing vallate papillae connective tissue core (arrow), H and E x480

In the 105 days old fetuses, the lingual papilla looked continued to mature with some rudiments of taste buds apparent on the fungiform papillae. The presence and maturation of the filiform papillae was also apparent (Fig. 6 and 7). Muscle fibres and connective tissues look well developed.

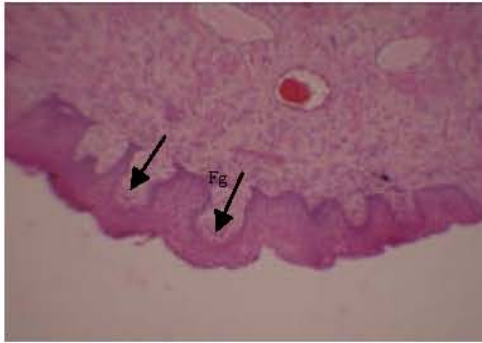


Fig. 6: One hundred and five days fungiform papillae and rudiment of taste buds (arrow), H and E x120

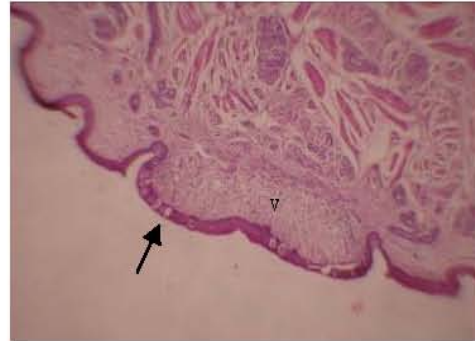


Fig. 8: One hundred and twenty days well-developed vallate papillae and taste buds (arrow), H and E x48

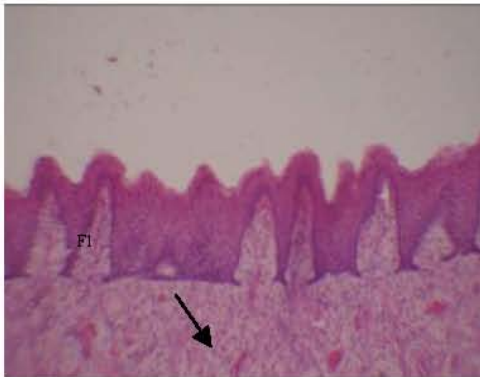


Fig. 7: One hundred and five days maturing filiform papillae, muscle fiber (arrow), H and E x480

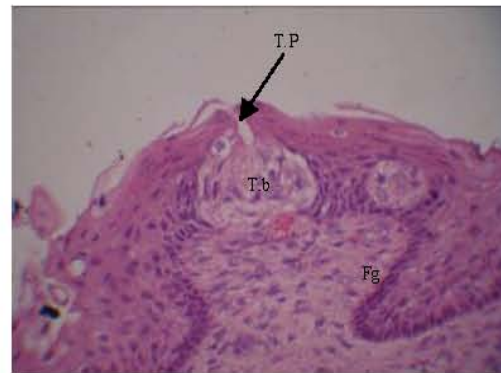


Fig. 9: One hundred and twenty days well-developed fungiform papillae and taste bud cell with taste pore (arrow), H and E x480

In 120 days old foetuses there was further maturation of the papillae and it showed filiform, fungiform and vallate papillae, with the lamina propria showing full differentiation (Fig. 8), taste buds were well developed and shows basal cell, supporting cell and neuroepithelial cell (Fig. 9). Muscle bundle, collagenous fibres, blood vessels, nerves bundle and gustatory glands were well developed (Fig. 10). The observations under light microscopy made it possible to following the developmental changes in the mucous membrane of the tongue from day 60-120 of prenatal life in camel. The study focused on the development and morphology of primordial some of the lingual papillae.

The observations were made in sections of specimen in median, transverse and dorsal planes. It was observed that at 60 days old foetal life, the epithelium covering the dorsum of the examined apex, body and root the tongue have about 4-6 layers of the epithelium, showing thickening of the epithelium. Rudimentary evidence of future papillae formation was observed at this age. The mesenchymal tissue was located under the epithelium, which is found on a well-defined basement membrane.

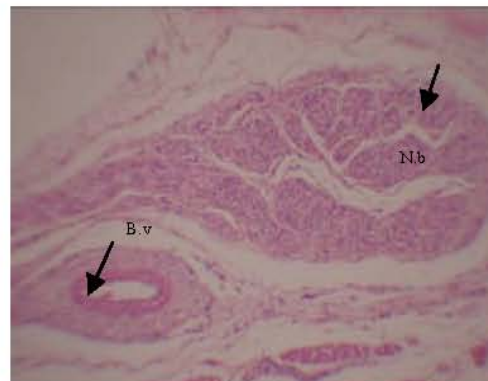


Fig. 10: One hundred and twenty days well-developed nerve bundle and blood vessel (arrow), H and E x120

The lamina propria of the mucosa was scant. The 75-105 days old foetuses showed apparent primordial of different papillae, with additional thickening of the epithelium. The observed thickenings represent the first forms of

primordial of fungiform and filiform papillae. Descriptions of the development of lingual papillae of mouse, rat and human has shown that early developmental stage of dome shaped structures found in the surface of the tongue were primordial of fungiform papillae (Iwasaki *et al.*, 1996b, 1997; Witt and Reutter, 1997).

Skeletal muscles fibers, blood vessels and some serious gustatory glands were well developed for 105 days old fetuses. The observations of Cho *et al.* (2005) in fetuses and neonates of Korean native goat (*Capra hircus*) shows that skeletal muscle and some serious gustatory glands were fully developed in 90 days old. In this study, the development of the filiform and fungiform papillae apparently started about 105 days of foetal life.

The studies of Iwasaki and Kumakura (1994) showed that the dorsal epithelium of the tongue in rats at the middle or late period of gestation has no rudiments of filiform papillae. In contrast, the rudiments of filiform papillae are clearly recognizable in the dorsal epithelium of the tongue of newborn rats just before birth; this morphogenesis of the filiform papillae of rats seems to occur rapidly during only 2 or 3 days, just before birth in parallel with keratinization of epithelium. It appears that different factors affect the morphogenesis of rudiments of lingual papillae.

Thus agents such as growth factors and hormones (Iwasaki *et al.*, 1997) should be examined for the role in different stages before and after birth to clarify the mechanism of morphogenesis of lingual papillae and differentiation of cells with different degrees of keratinization.

The tongue is found in all vertebrates except fishes and some amphibians and the undulation as of the dorsal lingual surface are recognizable as a common feature of the tongues of most animals from amphibian to mammals (Iwasaki and Kamakura, 1994; Iwasaki *et al.*, 1996a, b, 1997). Among reptiles (Iwasaki and Kamakura, 1994), the keratinization of lingual epithelium is to adapt to dry land from fresh-water environment. Igbokwe and Okolie (2009) shows that the dorsum of the tongue of the prepubertal (Red Sokoto goat) is lined by keratinized stratified squamous epithelium.

The superficial cells had polygonal shape with distinct bodies. Similar features were reported in horse (Chamorro *et al.*, 1986), mouse (Watanabe and Ogawa, 2007).

According to Farbman and Mbiene (1991), there is an intimate relationship between the feeding habits and the development of the vallate papillae. The findings showed that the connective tissue of vallate papillae present a central groove surrounded by connective tissue papillae with different height.

## CONCLUSION

There are significant complex changes during the development of the mucous membrane of the tongue and its papillae during the period from day 60-120 of prenatal period, which is continued in the postnatal life.

## REFERENCES

- Ahpin, I., S. Ellis, C. Arnott and M.H. Kaufman, 1989. Prenatal development and innervations of the circumvallate papillae in the mouse. J. Anatomy, 162: 33-42.
- Chamorro, C.A., P.C. de Paz, J. Sandoval and F. Fernandez, 1986. Comparative scanning electron microscopic study of the lingual papillae in two species of domestic mammals (*Equus caballus* and *Bostaurus*). 1: Gustatory Papillae. Acta Anat., 125: 83-87.
- Cho, C.H., C.S. Kim, P.O. Koh, B.I. Kang, J.H. Lee and C.K. Won, 2005. Morphological study on the development of the tongue in fetuses and neonates of Korean native goat (*Capra hircus*). Korean J. Vet. Res., 45: 477-484.
- Eurell, J.A., B.L. Frappier and H. Dellmann, 2006. Textbook of Veterinary Histology. 6th Edn., Lea and Febiger, Philadelphia, pp: 174-175.
- Farbman, A.I. and J.P. Mbiene, 1991. Early development and innervation of taste bud-bearing papillae on the rat tongue. J. Comp. Neurol., 304: 172-186.
- Fawcett, D.W. and E. Raviola, 1994. Bloom and Fawcett, a Textbook of Histology. 12th Edn., Chapman and Hall New York.
- Fujimoto, S., K. Yamamoto, M. Yoshizuka and M. Yokoyama, 1993. Pre and post-natal development of rabbit foliate papillae with reference to foliate gutter formation and taste bud and serous gland differentiation. Microscopy Res. Technol., 26: 120-132.
- Igbokwe, C.O. and C. Okolie, 2009. The morphological observations of some lingual papillae in the prenatal and prepubertal stages of Red Sokoto goats (*Capra hircus*). Int. J. Morphol., 27: 145-150.
- Iwasaki, S. and M. Kumakura, 1994. An ultrastructural study of the dorsal lingual epithelium of rat snake (*Elaphe quadrivigata*). Ann. Anat., 176: 455-462.
- Iwasaki, S., H. Yoshizawa and I. Kawahara, 1996a. Study by scanning electron microscopy of the morphogenesis of three papillae in the mouse. Acta Anat., 157: 41-52.



- Iwasaki, S., C. Wanichanon and T. Asami, 1996b. Histological and ultrastructural study of the lingua l epithelium of juvenile pacific turtle *Lepidochelys olivacea* (Chelonia, Cheloniidae). *Ann. Anatomy*, 178: 243-250.
- Iwasaki, S., H. Yoshizawa and N. Kawahara, 1997. Study by scanning electron microscopy of the morphogenesis of three types of lingual papilla in the rat. *ARPDMCEB*, 247: 528-541.
- Kulawik, M., 2005a. Themucous membrane of the tongue, with special emphasis on fungiform papillae in the period from day 1 to month 6 of postnatal life in the rabbit. *Acta Sci. Pol. Med. Vet.*, 4: 47-58.
- Kulawik, M., 2005b. The development of the mucous membrane of the tongue with special emphasis on the development of fungiform papillae in the prenatal life of the rabbit. *Electron J. Polish Agric. Univ.*, 8: 4-4.
- McGeady, T.A., P.J. Quinn, E.S.F. Patrick and M.T. Ryan, 2006. *Veterinary Embryology*. 1st Edn., Blackwell Publishing Ltd., UK.
- Tichy, F., 1992. The morphogenesis of selected lingual papillae in ovine and porcine fetuses observed by scanning electron microscopy. *Acta Vet. Brno.*, 61: 3-10.
- Watanabe, I. and K. Ogawa, 2007. Ultrastructure of the adhesion of bacteria to the epithelial cell membrane of three-day postnatal rat tongue mucosa: a transmission and high-resolution scanning electron microscopic study. *Braz. Dent. J.*, 18: 320-323.
- Witt, M. and K. Reutter, 1997. Scanning electron microscopic studies of developing gustatory papillae in humans. *Chem. Senses*, 22: 601-612.