

Pre-Natal Growth of the Tongue and Development of the Lingual Papillae in Sahel Goats (*Capra hircus*)

¹J.C. Shawulu, ²H.D. Kwari and ²A.Y. Abgyal

¹Department of Veterinary Anatomy, University of Abuja, Abuja

²Department of Veterinary Anatomy, University of Maiduguri, Maiduguri

Abstract: This study was carried out to investigate the growth of the tongue and the morphological development of lingual papillae in Sahel goat fetuses using the light microscopy. A total of 20 fetuses of the Sahel goat were used. Evidence of scanty connective tissues and blood vessel formation was observed as early as 9-10 weeks of gestation. The least tongue weight and length were 104.7 ± 63.2 g and 2.4 ± 1.0 cm at 6-7 weeks of gestation. The highest was 645.3 ± 310.0 g and 5.5 ± 0.4 cm in 15-17 weeks old, respectively. Tongue mucosal epithelia were observed to be thickened with 4-6 layers of cells at 6-7 weeks of gestation. Papillary differentiations were evident with connective tissue and lamina propria underlying them by 12-13 weeks. By 15-17 weeks of gestation various papillae are distinguished by their heights and sizes. Rudiments of taste buds were also observed in vallate papillae at 15-17 weeks of age.

Key words: Pre-natal, growth, development, lingual papillae, Sahel goats, fetuses

INTRODUCTION

The tongue in mammals is an extremely muscular organ within whose substance there are a number of smaller salivary glands and any number of motor and sensory nerve fibers (Sisson and Grossman, 1975; Dyce *et al.*, 1996). The bulk of the tongue is skeletal muscle, arranged in three layers all at right angles to each other (Sisson and Grossman, 1975; Reece, 2004) giving it a degree of flexibility needed for prehension and manipulation of food (Getty, 1975; Dyce *et al.*, 1996).

The surface anatomy of the tongue of the domestic animals have been described by several researchers goat (Kumar *et al.*, 1998; Cho *et al.*, 2005; Igbokwe and Okolie, 2009), the sheep (Tichy, 1991; Emura *et al.*, 2000; Tadjalli, 2004), the camelus dromedarius (Salehi *et al.*, 2010), etc. The use of the senses of taste, smell and sight appears to predominate in forage preference and feeding behavior in grazing animals with complex interactions. No one sense seems to predominate over the other in every situation any way however, it is commonly believed that taste is the most important sense in forage selection and the identification of palatability of food for the animal (Vallentine, 1990; Peacock, 1996). It is no doubt that the tongue presents variable papillae for either taste of substances or mechanical functions as seen in the cat (Boshell *et al.*, 1982). Taste sensation initiated within some papillae found in all vertebrates animals is however, difficult to quantify and is thought to be directed more

towards selecting tastes that are harmless or harmful to them than to enjoy or dislike compared to the humans (Aspinall *et al.*, 2009).

This study is aimed at studying the prenatal developmental changes of the tongue of the Sahel goat (*Capra hircus*) one of the major breed in Nigeria and to determine structural readiness for taste buds. The report will also add to the existing information on the morphogenesis of the tongue in Sahel breed of goat.

MATERIALS AND METHODS

A total of 20 fetal tongue samples of both sexes of the Sahel goat breed in Nigeria were used in this study. The goats were obtained from Maiduguri township abattoir. After physical examination, they were aged using the developmental horizons described by Richardson *et al.* (1976) and Sivachelvan *et al.* (1996). Body weights were taken and tongues removed by excision at the radix linguae.

Tongue lengths and weights were measured using a tape and a microwa® sensitive balance. The specimens were washed in saline solution and fixed 10% formalin solution as described by Baker and Silverton (1985). Sections of 10 μ were produced and stained with Haematoxylin and Eosin (H and E) staining method as described by Luna (1968). Slides were studied and photomicrographed using the Cannon® camera 8.0 mega pixels mounted on a light microscope. The morphometrical

data obtained were subjected to Analyses of Variance (ANOVA) using the Turkey-Kramer Graphpad Instat® software. The results were expressed as mean±SD at 5% degree of significance.

RESULTS AND DISCUSSION

Morphologically, the tongues were initially (6-8 weeks of gestation) firm pale smooth, oblong in shape and variable in size relative to the ages studied. They turn brown at the age of 9-10 weeks of gestation (Fig. 1), indicative of the development of the blood vessels supplying the tongue. This is in conformity with the findings of Shawulu *et al.* (2010) of the formation of renal vasculature at the same age in Sahel goat. Mean body weight ranges between 104.7±63.2 g in 6-7 weeks old and 645.3±310.0 g in 15-17 weeks old fetuses. This corresponds to tongue weights of 1.2±0.4 and 4.0±1.4 g, respectively. Similarly, the crown-rump lengths of 13.5±3.0 cm in 5-8 weeks old and 32.0±5.4 cm in 15-17 weeks old corresponds to tongue lengths of 2.4±1.0 and 5.5±0.4 cm, respectively (Table 1). Both the relative and percentile increases in body and tongue

weights were higher during the 1st and 2nd quarter of the gestation period (154.32, 1.04 g and 114, 80%), respectively. Histologically, fetuses at 6-7 weeks of gestation had epithelial lining of the dorsal apex of the tongue to be thickened with about 4-6 cell layers than observed in the red Sokoto goats at similar age by Igbokwe and Okolie (2009) (Fig. 2). This observation corresponds to the findings of Salehi *et al.* (2010) in dromedaries of similar age of gestation. About 6-8 primitive filiform papillae were observed protruding the basal lamina of the tongue. Kumar *et al.* (1998) had reported that in Jamunapari goats. Desquamation of epithelia was also evident at some areas, indicative of the differentiation into definitive papillae (Fig. 3).

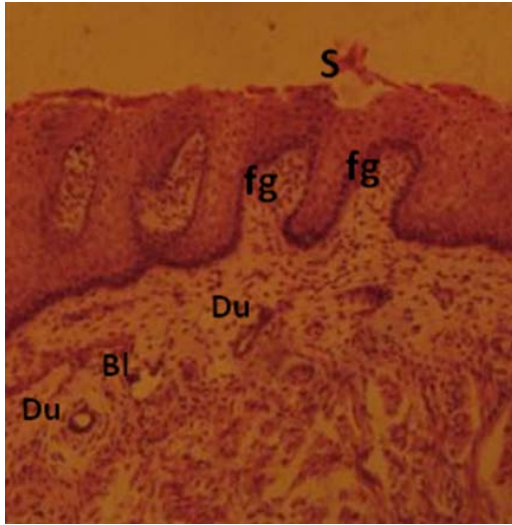


Fig. 1: Blood vessel (Bl), rudiments of fungiform papillae (fg), mucosal glands Ducts (Du) and desquamation of epithelia (S) at 9-10 weeks of gestation. H and E x100

Table 1: Mean±SD of the Sahel goat fetal body weight, tongue weight and lengths based on age

Age (weeks)	Body weights (g)	Crown-rump lengths (cm)	Tongue weights (g)	Tongue lengths (cm)
6-7 (n = 6)	104.7±63.20	13.5±3.0	1.2±0.4	2.4±1.0
9-10 (n = 5)	221.6±71.20	18.8±2.2	1.4±0.8	3.7±0.3
112-13 (n = 5)	425.6±108.5	25.6±1.2	2.6±0.8	5.3±0.4
115-17 (n = 4)	645.3±310.0	32.0±5.4	4.0±1.4	5.5±0.4

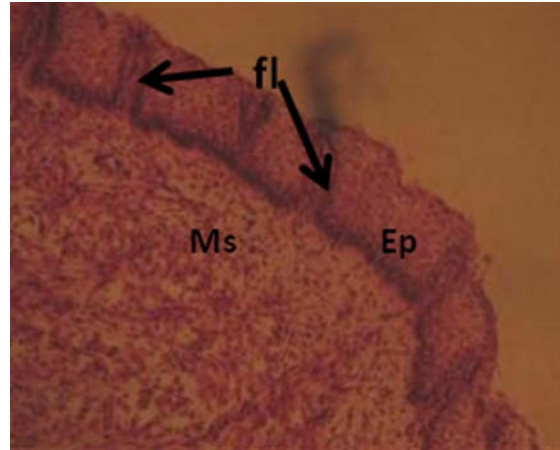


Fig. 2: Epithelial lining (Ep), primitive filiform papillae (fl) and Mescenchymal tissue (Ms) at 6-7 weeks of gestation. H and E x100

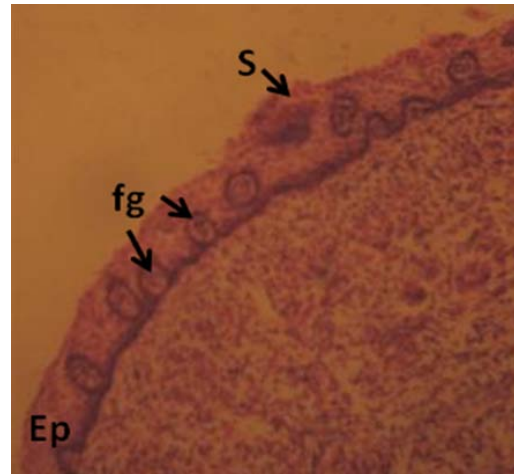


Fig. 3: Epithelial lining (Ep), primitive fungiform papillae (fg) and evidence of desquamation of the epithelia (S) at 6-7 weeks of gestation. H and E x100

The basal lamina which was initially somewhat flat became rugged with the underlining mesenchyme forming the core of papillae. Varying degrees of ridgelike elevations forming fungiform papillae from the dorsum linguae were evident at the age of 9-10 weeks of gestation (Fig. 4). This is in agreement to the report by Tichy (1992) in Ovine fetuses of the same age.

Fungiform papillae become more elongated with varying depths and sizes. These are filled with detritus resulting from epithelial desquamation noticeable on the dorsum of the ridges (Fig. 5). At 12-13 weeks of gestation, vallate papillae primordia were apparent, encircled by

vallums slightly protruding above the level of the mucosa (Fig. 6). They are situated in rows observed at the lateral aspect of the radix linguae. Muscle tissues and connective tissues are well developed. However, no evidence of taste buds noticed.

Vallate papillae become distinguished by their heights and sizes having clefts into their surroundings at 15-17 weeks of gestation (Fig. 7). At this stage presence of rudiments of taste buds were noticed. The tongue is yet to be fully developed and the process could be completed post-natally. Kubota (1968) had reported that feeding habit and the development of vallate papillae have a relationship.

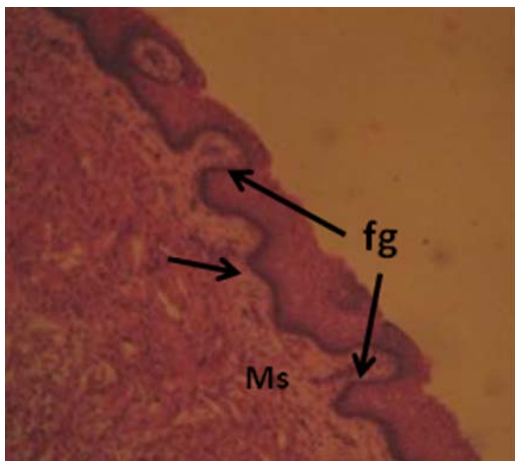


Fig. 4: Rudiments of fungiform papillae (fg), connective tissue and Muscles (Ms) and undulating lamina propria (arrow). H and E x100

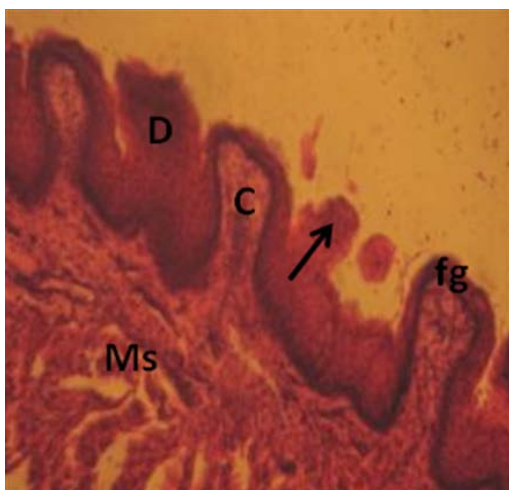


Fig. 5: Fungiform papillae (fg), evidence of keratinization of the epithelia (arrow), Detritus (D) at 12-13 weeks of gestation. H and E x100

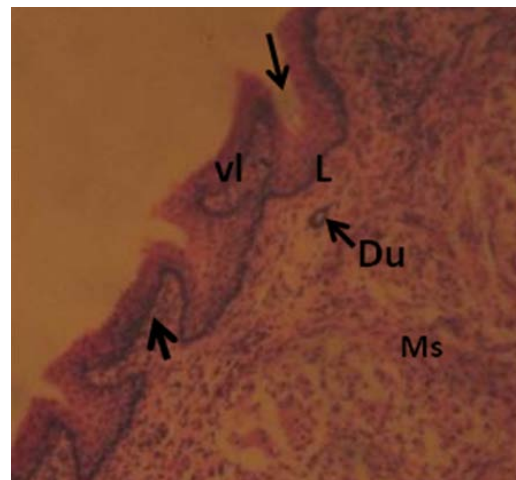

Fig. 6: Vallate papillae (vl), Lamina propria (L), connective tissue core (arrow) and Muscle fibers (Ms) at 12-13 weeks of gestation. H and E x100

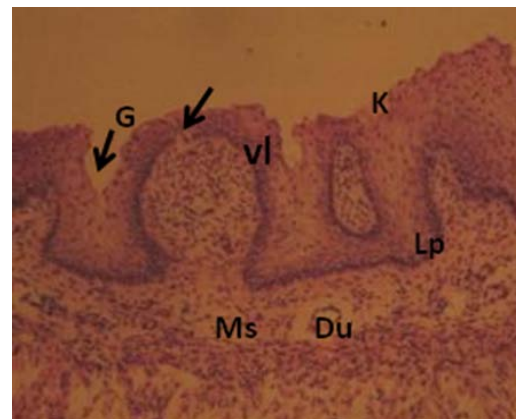

Fig. 7: Vallate papillae (vl), primitive taste bud (arrow), lamina propria (lp), gland Ducts (Du), Groove (G), Keratinization (K) at 15-17 weeks of gestation. H and E x400

The developmental changes are influenced by both genetic factors as well as environmental factors reported by Jainudeen and Hafez (1993). It is probable that these factors may have interplay role in any variation obtained in this study to other goat species. Also, the factors and hormones of growth reported by Iwasaki *et al.* (1997) needs to be evaluated for their roles in the different stages of prenatal differentiation of cells forming papillae at different stages.

The keratinization observed at earlier stage (12-13 weeks) in this specie enables it perform well considering its adaptational mechanisms in the semi-desert and desert areas of Nigeria.

CONCLUSION

This study has described the selected stages of morphogenesis of some lingual papillae in Sahel goat fetuses. Cornical and foliate papillae were not observed. Much attention was given to the differentiation of the lingual mucosa and the formation of gustatory pores in fungiform and vallate papillae. It is important to note that there are significant but complex changes that occur in the differentiation of the mucous membrane of the Tongue during the period from week 6-17 (42-120 days) of pre-natal development of the fetus in Sahel goat.

ACKNOWLEDGEMENTS

The researchers would like to express thier thanks to Mr. Ibrahim, M. Wiam and Dr. E.I. Ajayi for their technical assistance.

REFERENCES

- Aspinall, V., M. Cappello and A. Jeffery, 2009. Introduction to Veterinary Anatomy and Physiology. 2nd Edn., Butterworth Heinemann, China, Pages: 238.
- Baker, F.J. and R.E. Silvertown, 1985. Introduction to Medical Laboratory Technology. 6th Edn., Butterworths, London, Pages: 480.
- Boshell, J.L., W.H. Wilborn and B.B. Singh, 1982. Filiform papillae of cat tongue. *Acta Anat. (Basel)*, 114: 97-105.
- Cho, C.H., C.S. Kim, P.O. Koh, B.I. Kang, J.H. Lee and C.K. Won, 2005. Morphological studies on the development of the tongue in fetuses and neonates of Korean native goat (*Capra hircus*). *Korean J. Vet. Sci.*, 45: 477-484.
- Dyce, K.M., W.O. Sack and C.J.G. Wensing, 1996. Textbook of Veterinary Anatomy. 2nd Edn., W. B. Saunders Co., Philadelphia.
- Emura, S., A. Tamada, D. Hayakawa, H. Chen and S. Shoumura, 2000. Morphology of the dorsal lingual papillae in the barbary sheep, *Ammotragus lervia*. *Okajimas Folia Anat. Jpn.*, 77: 39-45.
- Getty, R., 1975. The Anatomy of Domestic Animals. 5th Edn., W.B. Saunders Co., Philadelphia, pp: 1583.
- Igbokwe, C.O. and C. Okolie, 2009. The morphological observations of some lingual papillae in the prenatal and prepuberal stages of Red Sokoto goats (*Capra hircus*). *Int. J. Morphol.*, 27: 145-150.
- Iwasaki, S., H. Yoshizawa and N. Kawahara, 1997. Study by electron microscopy of three lingual papillae in the rat. *Anat. Rev.*, 247: 528-541.
- Jainudeen, M.R. and E.S.E. Hafez, 1993. Gestation Pre-Natal Physiology and Parturition. In: Reproduction in Farm Animals, Hafez, E.S.E. (Eds.). Lea and Febiger, Philadelphia, pp: 213-235.
- Kubota, K., 1968. Comparative anatomy and neurophysiological observations on the tongue of Northern fur seal. *Anat. Rev.*, 161: 257-266.
- Kumar, P., S. Kumar and Y. Singh, 1998. Tongue Papillae in goat: A scanning electron-microscopic study. *Anat. Histol. Embryol.*, 27: 355-357.
- Luna, L.G., 1968. Manual of Histological Staining Methods of the Armed Forces Institute of Pathology. 3rd Edn., The Blakiston Division, McGraw-Hill Book Co., New York.
- Peacock, C., 1996. Improving Goat Production in the Tropics: A Manual for Development Workers. Farm Africa and Oxfam Publishing, UK., pp: 400.
- Reece, W.O., 2004. Physiology of Domestic Animals. 12th Edn., Williams and Wilkins, USA., Pages: 502.
- Richardson, C.M., C.N. Heubert and C. Terlecki, 1976. Estimation of developmental age of ovine foetus and lamb. *Vet. Rev.*, 99: 22-24.
- Salehi, E., I. Pousti, H. Gilanpoor and M. Adibmoradi, 2010. The morphological observations of some lingual papillae in camelus dromedaries embryos. *J. Anim. Vet. Adv.*, 9: 514-518.
- Shawulu, J.C., M.N. Sivachelvan, H.D. Kwari and A. Yahaya, 2010. Fetal growth and developmental changes in the kidneys of Sahel goat in Nigeria. *J. Res. Biosc.*, 6: 33-39.
- Sisson, S. and J.D. Grossman, 1975. The Anatomy of the Domestic Mammals. 4th Edn., W.B. Saunders, Philadelphia, pp: 558-563..
- Sivachelvan, M.N., A.M. Ghali and G.A. Chibuzo, 1996. Fetal age estimation in sheep and goat. *Small Rumin. Res.*, 19: 69-76.

- Tadjalli, M., 2004. Scanning electron-microscopic study of the lingual papillae in newborn lambs. *Iran. J. Vet. Res.*, 5: 21-28.
- Tichy, F., 1991. The Morphogenesis of circumvallate papillae and the differentiation of taste buds in the pig at 41 to 84 days of prenatal development. *Acta Vet. Brno*, 60: 99-110.
- Tichy, F., 1992. The morphogenesis of selected lingual papillae in ovine and porcine foetuses observed by scanning electron microscopy. *Acta Vet. Brno*, 61: 3-10.
- Vallentine, J.F., 1990. *Grazing Management*. Academic Press Inc., San Diego, Pages: 528.